

Diclofenac sodium and Allopurinol induced Stevens_Johnson Syndrome in pulmonary tuberculosis patients receiving intensive phase first-line antituberculosis drugs

World Journal of Biological and Pharmaceutical Research, 2023, Vol 4, Issue 2

Article DOI: 10.53346/wjbpr.2023.4.2.0051

Desdiani Desdiani *

Department of Pulmonology and Respiratory Medicine, Faculty of Medicine, Sultan Ageng Tirtayasa University, Serang, Banten, Indonesia.

Received on 23 April 2023; revised on 02 June 2023; accepted on 05 June 2023

Daftar Isi

Daftar Isi	2
Author Declaration Form	3
Submitted Manuscript	4
Cover Letter 30 Mei 2023	9
Submission New 30 Mei 2023	11
Editorial Decision	12
Article Proof and Final Check	14
Article Proof for Final Check (From Author)	16
Article Accepted	18
Author Queries	23
Article Published	25

Author Declaration Form



World Journal of Biological and Pharmaceutical Research
(WJBPR)

Author's Declaration Form

Manuscript number: WJBPR-_____

Title of article: **Diclofenac sodium and Allopurinol induced Stevens Johnson Syndrome in pulmonary tuberculosis patients receiving intensive phase first-line antituberculosis drugs**

Corresponding Author's name: **Desdiani Desdiani, MD, Ph.D**

Names of co-authors: -

E-mail of corresponding author. : desdiani@vmail.com

The author(s) acknowledged that:

- 1) All authors have read, understand and agreed to the submission guidelines, policies and submission declaration of the journal.
- 2) The manuscript is the authors' original work and has not been published or is not being submitted or considered for publication elsewhere.
- 3) All authors have checked the manuscript for plagiarism and declare that manuscript is plagiarism free. However, in future if any one report/complain about plagiarized part or text in the manuscript, authors will be responsible for the action (retraction) taken by journal editors/publisher.
- 4) All authors have seen and approved the manuscript as submitted.
- 5) All authors participated in the work in a substantive way and are prepared to take public responsibility for the work.
- 6) All authors of the manuscript have no conflict of interests to declare.
- 7) The text, illustrations, and any other materials included in the manuscript do not infringe upon any existing copyright or other rights of anyone.
- 8) Submission of false or incorrect information/undertaking would invite appropriate penal actions as per norms/rules of the journal.
- 9) All authors shall not submit the paper for publication in any other Journal or Magazine till the decision is made by journal editors.
- 10) All authors confirm that upon acceptance of the paper, they will publish the paper by paying Article Processing Charges (APC), or withdraw it by paying Withdrawal Fee.

Date: 30th May 2023
Place: Serang, Banten, Indonesia

Signature

Diclofenac sodium and Allopurinol induced Stevens Johnson Syndrome in pulmonary tuberculosis patients receiving intensive phase first-line antituberculosis drugs

Desdiani Desdiani^{1*}

¹Department of Pulmonology and Respiratory Medicine, Faculty of Medicine, Sultan Ageng Tirtayasa University, Serang, Banten, Indonesia

*Corresponding author: Desdiani Desdiani, MD, Ph.D

Faculty of Medicine, Sultan Ageng Tirtayasa University, Jalan Raya Jakarta Km.04 Pakupatan, Serang, Banten, Indonesia 42124

Tel +62254280330, Fax: +62254281254

E-mail: desdiani@vmail.com

Abstract

One of the life-threatening multi-organ emergency conditions is Stevens-Johnson Syndrome (SJS). Although this is a rare disease and manifests as drug reactions, this condition can cause death. We present a case of a 63-year-old male with Diclofenac sodium and Allopurinol induced Stevens Johnson Syndrome in pulmonary tuberculosis patients receiving intensive phase first-line antituberculosis drugs. The patient was undergoing outpatient TB treatment at the end of the first month. The patient comes to the emergency department of the hospital because of shortness of breath, fever, blistered skin, nasal and oral mucosa, cracks and wounds, visible pus, red eyes accompanied by erythematous rash all over the body after previously taking diclofenac sodium and allopurinol given by the doctor because of joint pain all over body and uric acid increased. On physical examination of the lungs, crackles and wheezing were heard in both lung fields. The chest radiograph shows infiltrates in both lung fields. Laboratory results showed leukocytosis and the results of other blood laboratory tests were still within normal limits. Patient diagnosed Stevens-Johnson Syndrome based on clinical, laboratory, and radiology examination results. The patient was given treatments using nasal cannula oxygen of 5 litres/minute, intravenous fluid dehydration D5% : NaCl 0.9%, ceftriaxone injection, gentamicin injection, dexamethasone injection, cetirizine ranitidine injection, compresses with 0.9% NaCl liquid, 2.5% hydrocortisone ointment. The patient was treated in the Intensive Care Unit for 8 days. The patient had no history of previous drug allergies. In this case, the likelihood of Diclofenac sodium and Allopurinol induced Stevens Johnson Syndrome in pulmonary tuberculosis patients receiving intensive phase first-line antituberculosis drugs, needs to be a concern, as well as the importance of evaluation and strict follow-up to prevent Stevens Johnson Syndrome disease.

Keywords: Stevens Johnson Syndrome, Diclofenac sodium, Allopurinol, Antituberculosis drug

INTRODUCTION

Steven Johnson Syndrome is a rare vesiculo bullous disease characterized by acute skin eruption involving the skin and mucous membranes. This hypersensitivity reaction characterized by hyperpigmentation, skin rashes, target skin lesions involving blistering, erosion over face, trunk and limbs. Some studies reveal the incidence of SJS to be around 1.2-6 patients per 1 million per year. Some studies show that there are more men experiencing SJS.[1] More than 100 types of drugs have been reported to have potential cause SJS[2-4] SJS patients have a high mortality rate. Main therapy SJS patients are supportive treatment and other treatment options.

Diclofenac sodium is a type of nonsteroidal anti-inflammatory drug (NSAID) which is most widely used as an analgesic drug. Several studies have revealed cases of mucocutaneous drug reactions secondary to NSAID treatment.[5] Allopurinol is the first-line therapy for gout but carries the risk of serious side effects. Stevens-Johnson syndrome (SJS) is one of the causes of severe cutaneous adverse reactions that can be life-threatening. The degree of severity of the disease is based on the extent of the skin affected. Several mechanisms related to SJS have been formulated. One of the mechanisms is the formation of haptened products produced by the combination of allopurinol with self peptide which is mediated by the activation of specific T cell antigens.[6]

Many studies revealed the effect of anti-tuberculosis drugs on the incidence of drug-induced hepatitis, influenza-like diseases, arthralgia, and other skin reactions, which in severe forms are mediated by immunological processes, namely Stevens-Johnson syndrome (SJS), toxic epidermal necrolysis (TEN), drug reactions, with eosinophilia and systemic symptoms. Although all anti-tuberculosis drugs carry the risk of inducing Stevens-Johnson syndrome, rifampicin is most commonly associated with its occurrence.[7]

CASE

A 63-years-old male was admitted to the emergency unit of the hospital with shortness of breath, the skin blisters, the nose and mouth mucosa looks broken and sore, red nodules with pus accompanied by red rashes all over the body (Figure A-D). The patient is undergoing intensive phase TB treatment at the end of the first month. The patient had complained of itching since the first week of taking TB medication and it got better after taking cetirizine. The patient then took diclofenac sodium and allopurinol given by the doctor because he felt joint pain all over his body and increased uric acid. The patient still appeared conscious but weak and had a fever of 39^o C. On physical examination of the lungs, crackles and wheezing were heard in both lung fields. The chest radiograph showed infiltrates in both lung fields. Laboratory results showed leukocytes 16,800cells/ μ and eosinophils 7%. Patients diagnosed with Diclofenac sodium and Allopurinol induced Stevens Johnson Syndrome in pulmonary tuberculosis patients receiving intensive phase first-line antituberculosis drugs based on clinical, laboratory, and radiology examination results. The patient was given treatments using a nasal cannula oxygen of 5 litre/minute, intravenous fluid dehydration D5% : NaCl 0.9% with a ratio of 3 : 1. The patient was also given treatments with ceftriaxone injection, zentamicin injection, dexamethasone injection, cetirizine ranitidine injection, compress

0.9% NaCl liquid 2 x 15 minutes on chafed lips, eyes and genitals, orabase 2 x daily, 2.5% hydrocortisone ointment 2 x daily for boils. The patient was treated in the Intensive Care Unit for 8 days. Day 9 the patient's condition improved and the wound began to dry. The patient was transferred to the inpatient room, and 3 days later was scheduled to be discharged. The patient has no previous history of drug allergies and has no comorbidities in his medical history (eg hypertension, diabetes mellitus, autoimmune disease, or malignancy). In this case, the likelihood of Diclofenac sodium and Allopurinol induced Stevens-Johnson Syndrome in pulmonary tuberculosis patients receiving intensive phase first-line antituberculosis drugs, needs to be concerned, as well as the importance of evaluation and strict follow-up to prevent Stevens-Johnson Syndrome disease.

DISCUSSION

Stevens-Johnson syndrome is a severe systemic disorder that has the potential to cause severe morbidity and death. SJS is a rare vesiculobullous disease characterized by acute skin eruptions involving the skin and mucous membranes. This is a type 4 hypersensitivity reaction with severe skin symptoms and is often accompanied by complications to several organs such as the liver, kidneys and lungs. The area of skin involved in Steven-Johnson Syndrome and toxic epidermal necrosis is divided as the degree of epidermal detachment of less than 10% of the body surface is called SJS, 10-30% is considered a mixture of SJS and toxic epidermal necrosis, >30% is considered toxic epidermal necrosis. The most common causes of SJS are drugs, which account for 80% of all cases of SJS, namely NSAIDs, allopurinol, carbamazepine, phenobarbital, phenytoin, valproic acid. SJS associated with NSAIDs is relatively rare. A study of 135 cases of skin reactions secondary to NSAID use showed that the oxicam class and its derivatives caused SJS the most compared to other types of NSAIDs. [8,9]

The exact pathogenesis of SJS remains to be further investigated, however, the mechanisms of apoptosis including the involvement of tumor necrosis factor, cytotoxic T cells- α , Fas (CD 95) and Fas ligand interactions are thought to be associated with this disease. The pathobiology of SJS involves specific immune reactions, specific alleles of human leukocyte antigen (HLA) to certain drug populations in the activation of cytotoxic T lymphocytes and natural killer cells. A variety of cytotoxic and immunological signals, hunched to mediate disseminated keratinocyte death and epidermal shedding in SJS. If this condition is not treated it can cause excruciating pain, fluid loss, massive protein loss, bleeding, evaporative heat loss with hypothermia and infection.[9,10] In this case, the patient appeared shortness of breath, fever, skin full of red rashes, pus nodules, blisters, sores especially on the oral and nasal mucosa. This condition was experienced after the patient who was undergoing TB therapy for the first month, took diclofenac sodium and allopurinol drugs.

The characteristic pattern of SJS is extensive necrotic keratinocytes or necrosis that causes the thickened epidermis. Vacuolized hemorrhages to subepidermal blisters are found on the basement membrane. Superficial lymphohistocytic infiltrates, often perivascular, may be seen in the upper dermis. While varying numbers of eosinophils were observed in tissue infiltrates on biopsy with Erythema multiforme major, Stevens-Johnson

syndrome and toxic epidermal necrosis. Another study revealed less epidermal necrosis, more dermal inflammation and exocytosis in erythema multiforme major compared to Stevens Johnson syndrome.[11] In this patient, skin blisters appeared, laboratory results of leukocytosis and eosinophilia.

The success of therapy is largely determined by early detection of disease, discontinuation of drugs suspected as the cause of SJS and intensive and supportive care in a hospital or Intensive Care Unit that is fully equipped. Several drug agents that are anti-inflammatory or immunosuppressive have been considered and tried as alternative therapeutic options, but there is no single drug that is effective and proven from clinical trials. The therapy given to this patient was D5% and NaCl 0.9% infusion, antibiotics, steroids, anti-inflammatory, anti-histamine, topical ointments and compresses. [12]

We reported one case with Diclofenac sodium and Allopurinol induced Stevens Johnson Syndrome in pulmonary tuberculosis patients receiving intensive phase first-line antituberculosis drugs. The likelihood of Diclofenac sodium and Allopurinol induced Stevens Johnson Syndrome in Pulmonary Tuberculosis patients, it is necessary to pay attention, especially to drugs taken by patients other than anti-tuberculosis drugs, especially the NSAID class, which are taken together with the consumption of tuberculosis drugs. Although all antituberculosis drugs carry a risk of skin eruptions and SJS, rifampicin is most commonly associated with allergic reactions and SJS may occur.

ACKNOWLEDGMENTS

The authors express gratitude to the staff of Bhayangkara Brimob Hospital who have contributed in providing medical data and records as well as all our patient who were involved in this report.

CONFLICT OF INTEREST

None declare

FUNDING

No funding was obtained

ETHICAL APPROVAL

Ethical approval is not required

CONSENT

Written informed consent for the publication of this study was obtained from the patient's family. A copy of the consent form is available upon request.

References

1. Sateesh Kumar Reddy K, Shannuga Kumar SD, Vijay Raghavendra NC, Sudheer Kumar K. A Case Report on Diclofenac Induced Stevens Johnson Syndrome. *J Basic Clin Pharma* 2018; 9(2): 109-110
2. Ward KE, Archambault R, Mersfelder TL. Severe adverse skin reactions to nonsteroidal antiinflammatory drugs: A review of the literature. *Am J Health Syst Pharm* 2010; 67(3):206-213. DOI: <https://doi.org/10.2146/ajhp080603>.
3. Morelli MS, O'Brien FX. Stevens-Johnson syndrome and cholestatic hepatitis. *Dig Dis Sci* 2001; 46(11):2385-8. DOI: <https://doi.org/10.1023/A:1012351231143>.
4. Roujeau JC, Kelly JP, Naldi L, et al. Medication use and the risk of Stevens-Johnson syndrome or toxic epidermal necrolysis. *N Engl J Med* 1995; 333(24):1600-1607. DOI: <https://doi.org/10.1056/NEJM199512143332404>.
5. Gupta SS, Sabharwal N, Patti R, Kupfer Y. Allopurinol-induced stevens-johnson syndrome. *American Journal of Medical Science* 2019; 357(4): 348-351
6. Jin HJ, Kang DY, Nam YH, Ye YM, Koh YI, Hur GY, et. al. Severe cutaneous adverse reactions to anti-tuberculosis drugs in korea patients. *Allergy Asthma Immunol Res* 2021; 13(2): 245-255
7. Stern RS, Biogby M. An expanded profile of cutaneous reactions to NSAIDS, Reporting to a specialty based system for spontaneous reporting of ADRs. *JAMA* 1984; 21:252-65.
8. Saha K. Toxic epidermal necrolysis; current concept in pathogenesis and treatment. *India Dermatol Venereal Leprol* 2000; 66:7-10.
9. Chism S, Chung CH. Update on pathobiology in SJS and TEN. *Dermatologic sinica* 2013;3:175-180.
10. Mockenhaupt M. The current understanding of SJS and TEN. *Expert review of Clinical Immunology* 2014;7:803-15.
11. HHFHo Diagnosis and treatment of SJS and TEN. *The Hong Kong Medical Diary* 2008;13:17-20.

COVER LETTER

Date 30th May 2023

To,
Editor-in-Chief,
World Journal of Biological and Pharmaceutical Research
(WJBPR)

Subject: submission of new manuscript for evaluation

Dear Sir/Madam,

I am enclosing herewith a manuscript entitled "**Diclofenac sodium and Allopurinol induced Stevens_Johnson Syndrome in pulmonary tuberculosis patients receiving intensive phase first-line antituberculosis drugs**" for possible evaluation as a **Case Report** in World Journal of Biological and Pharmaceutical Research (WJBPR). Stevens_Johnson Syndrome in pulmonary tuberculosis patients receiving intensive phase first-line antituberculosis drugs, needs to be a concerned, as well as the importance of evaluation and strict follow-up to prevent Stevens Johnson Syndrome disease.

All of the authors declare that they have all participated in the design, execution, and analysis of the paper, and that they have approved the final version. Additionally, there are no conflicts of interest in connection with this paper, and the material described is not under publication or consideration for publication elsewhere.

Thank you.

Sincerely,

Desdiani Desdiani, MD, Ph.D

Faculty of Medicine, Sultan Ageng Tirtayasa University, Jalan Raya Jakarta Km.04
Pakupatan, Serang, Banten, Indonesia 42124

Tel +62254280330, Fax: +62254281254

E-mail : desdiani@ymail.com

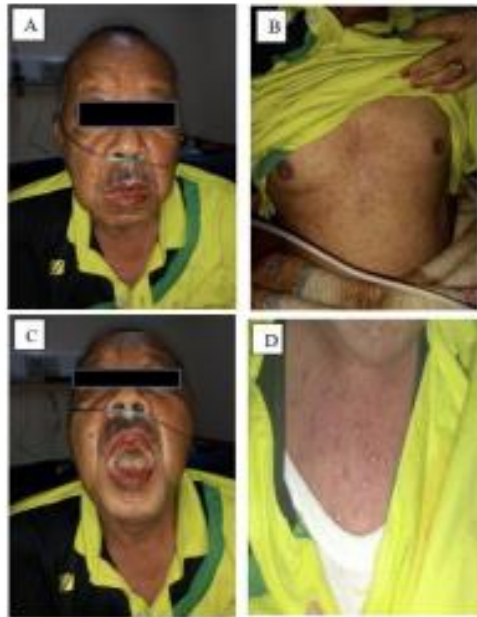

Figure A-D. Blistered skin, nasal and oral mucosa, cracks and wounds, visible pus, red eyes accompanied by erythematous rash all over the body

Submission New 30 Mei 2023

submission of new manuscript for evaluation

Dari: [desdiani - \(desdiani@gmail.com\)](mailto:desdiani@gmail.com)

Kepada: editor-wjbpr@zealjournals.com

Tanggal: Selasa, 30 Mei 2023 pukul 13.56 WIB

Dear Editor-in-Chief, of World Journal of Biological and Pharmaceutical Research,

Dear Sir/Madam,

I am enclosing herewith a manuscript entitled "**Diclofenac sodium and Allopurinol induced Stevens Johnson Syndrome in pulmonary tuberculosis patients receiving intensive phase first-line antituberculosis drugs**" for possible evaluation as a **Case Report** in World Journal of Biological and Pharmaceutical Research (WJBPR). Stevens Johnson Syndrome in pulmonary tuberculosis patients receiving intensive phase first-line antituberculosis drugs, needs to be a concerned, as well as the importance of evaluation and strict follow-up to prevent Stevens Johnson Syndrome disease.

All of the authors declare that they have all participated in the design, execution, and analysis of the paper, and that they have approved the final version. Additionally, there are no conflicts of interest in connection with this paper, and the material described is not under publication or consideration for publication elsewhere.

Thank you.

Sincerely,

Desdiani Desdiani, MD, Ph.D

Faculty of Medicine, Sultan Ageng Tirtayasa University, Jalan Raya Jakarta Km.04 Pakupatan, Serang, Banten, Indonesia 42124

Tel +62254280330, Fax: +62254281254

E-mail : desdiani@gmail.com



WJBPR Cover letter.docx
11.7kB



Case Report_Gunadi_Final.docx
23.9kB



WJBPR Authors Declaration form.docx
99.3kB

Editorial Decision

8/11/23, 1:01 PM

Yahoo Mail - Re: Editorial decision on your Manuscript (WJBPR-2023-0051): accepted for further publication process

Re: Editorial decision on your Manuscript (WJBPR-2023-0051): accepted for further publication process

Dari: desdiani - (desdiani@ymail.com)

Kepada: editor-wjbpr@zeajournals.com

Tanggal: Senin, 5 Juni 2023 pukul 13.32 WIB

Dear Author-in-Chief World Journal of Biological and Pharmaceutical Research (WJBPR)

We really appreciate the information you sent before. Therefore, we send you the Author's Declaration Form through attachment file in this e-mail.

Thank you for your attention and guidance

Best Regards

Desdiani Desdiani, MD, PhD

Pada Jumat, 2 Juni 2023 pukul 19.11.54 WIB, Editor WJBPR <editor-wjbpr@zeajournals.com> menulis:

Dear Author,
Greetings for the day..

We are pleased to inform you that your manuscript (Manuscript ref. no. WJBPR-2023-0051) entitled "*Diclofenac sodium and Allopurinol induced Stevens_Johnson Syndrome in pulmonary tuberculosis patients receiving intensive phase first-line antituberculosis drugs*" is approved for further publication process after editorial review.

In order to proceed for publication of your manuscript as fast as possible, follow the below steps

1) Provide Author's Declaration form (If not submitted earlier) and Author's name details. Your article cannot be published until the publisher has received the appropriate signed Author's Declaration form and filled Author's name details form (Download both forms from website. <https://zeajournals.com/wjbpr/content/downloads>)

2) Make the payment of Article processing charges: within seven working days after receipt of this e-mail using as details given below

A) Online payment through RazorPay: Using debit cards, or credit cards or Razorpay log in credential.

Amount payable through RazorPay is Total USD 32.00 (USD Thirty two only)

[Article processing fee (USD 30.00) + Transaction charges (USD 2.00)]

Click on link and follow instructions: <https://rzp.io/l/FRqdl5>

B) Online payment through PayPal: Using PayPal log in credential, debit cards, or credit cards.

Amount payable through PayPal is Total USD 32.00 (USD Thirty two only)

[Article processing fee (USD 30.00) + Transaction charges (USD 2.00)]

Click on below link and follow instructions: <https://zeajournals.com/content/paypal>

Author must e-mail copy of Payment details (Transaction ID) along with details involving Name of corresponding author, e-mail of corresponding author, manuscript number and Title of the manuscript to the editor of World Journal of Biological and Pharmaceutical Research (WJBPR) at editor-wjbpr@zeajournals.com.

If you need more information, feel free to contact us.

With Best Regards,
Managing Editor

8/11/23, 1:01 PM

Yahoo Mail - Re: Editorial decision on your Manuscript (WJBPR-2023-0051): accepted for further publication process

World Journal of Biological and Pharmaceutical Research (WJBPR)
editor-wjbpr@zeajournals.com



WJBPR Authors Declaration form (1).pdf
1.7MB

Author Declaration Form 5 Juni 2023



World Journal of Biological and Pharmaceutical Research
(WJBPR)

Author's Declaration Form

Manuscript number: WJBPR-.....

Title of article: Diclofenac sodium and Allopurinol induced Stevens Johnson Syndrome in pulmonary tuberculosis patients receiving intensive phase first-line antituberculosis drugs

Corresponding Author's name: Desdiani Desdiani

Names of co-authors:

E-mail of corresponding author : desdiani@ymail.com

The author(s) acknowledged that:

- 1) All authors have read, understand and agreed to the submission guidelines, policies and submission declaration of the journal.
- 2) The manuscript is the authors' original work and has not been published or is not being submitted or considered for publication elsewhere.
- 3) All authors have checked the manuscript for plagiarism and declare that manuscript is plagiarism free. However, in future if any one report/complain about plagiarized part or text in the manuscript, authors will be responsible for the action (retraction) taken by journal editors/publisher..
- 4) All authors have seen and approved the manuscript as submitted.
- 5) All authors participated in the work in a substantive way and are prepared to take public responsibility for the work.
- 6) All authors of the manuscript have no conflict of interests to declare.
- 7) The text, illustrations, and any other materials included in the manuscript do not infringe upon any existing copyright or other rights of anyone.
- 8) Submission of false or incorrect information/undertaking would invite appropriate penal actions as per norms/rules of the journal.
- 9) All authors shall not submit the paper for publication in any other Journal or Magazine till the decision is made by journal editors.
- 10) All authors confirm that upon acceptance of the paper, they will publish the paper by paying Article Processing Charges (APC), or withdraw it by paying Withdrawal Fee.

Date: 5th June 2023

Place: Serang, Banten

Signature

Article Proof and Final Check

WJBPR-2023-0051 Article proof for final check and approval

Dari: Editor WJBPR (editor-wjbpr@zealjournals.com)

Kepada: desdiani@gmail.com

Tanggal: Selasa, 6 Juni 2023 pukul 00.03 WIB

Dear Author,
Greetings for the day...

We are grateful for your association with us. Please find herewith attached final edited version (as a word file) of your manuscript (ref no. WJBPR-2023-0051) entitled "*Diclofenac sodium and Allopurinol induced Stevens-Johnson Syndrome in pulmonary tuberculosis patients receiving intensive phase first-line antituberculosis drugs*" which is accepted for publication in World Journal of Biological and Pharmaceutical Research (WJBPR).

Download Author proof copy of your manuscript:

<https://zealjournals.com/wjbpr/sites/default/files/Attached%20Files/WJBPR-2023-0051-01.docx>

Download Author query form:

<https://zealjournals.com/wjbpr/content/downloads>

Special Note:

1. Provide the name(s) of authors as First Name (Given name)-Middle Name- Last name (Family name/Surname) for each author and check that all names are accurately spelled. It is important from indexing purpose.
2. Use degree Celsius unit "°C" instead of superscript zero. Ex. "380 C" should be written as "38 °C".
3. Author should provide figures as author predict in manuscript (Highlighted text).
4. Author should provide an appropriate conclusion to the article. Write conclusion as single para. Conclusion should be concise, informative and can be started with summarizing outcome of the study in 1-2 sentence and ended with one line stating: how this study will benefit to the society and way forward.
5. Provide appropriate statement of ethical approval in the manuscript.
6. While writing reference citation in the main text at the end of sentence, author has put full stop before square bracket "[1]". It should be corrected by writing full stop after square bracket as "[1]". Check and correct throughout the manuscript.
7. Ensure that, all the references appearing in the text should be enlisted at the end in reference section and vice versa.

Without this we will not able to process your manuscript further.

We hereby request you that,

1. Read the proof at least thrice, note the errors and make necessary corrections (in blue colored text) to make the manuscript error free.
2. Do not change the format of the word file, just check the spelling and other errors in the attached text part.
3. Use this proof for checking the typesetting, editing, completeness and correctness of the text, tables and figures.
4. Significant changes to the article will only be considered at this stage with permission from the Editor.
5. Make sure that you send final approved copy of article proof along with duly filled Author proof form within 3 days after receipt of this e-mail.
6. Your manuscript will not be further processed for publication until and

unless we receive your final approved article proof and Author query form.
7. It is responsibility to author to check each and every word and spelling including italic and normal formatting of specific names. No changes will be accepted after this. If any changes are expected after publication of manuscript, author will have to pay charges accordingly.

We would appreciate to receive your corrected proof as a word file by e-mail within stipulated time period so that we can process your article quickly and efficiently.

Thank you for submitting your work to this journal.

If you need more information, please do not hesitate to contact us.

With Best Regards,
Managing Editor
World Journal of Biological and Pharmaceutical Research (WJBPR)
editor-wjpr@zealjournals.com

Article Proof for Final Check (From Author)

Re: WJBPR-2023-0051 Article proof for final check and approval

Dari: desdiani - (desdiani@gmail.com)

Kepada: editor-wjbpr@zealjournals.com

Tanggal: Selasa, 6 Juni 2023 pukul 14.03 WIB

Dear Editor-in-Chief of World Journal of Biological and Pharmaceutical Research (WJBPR)

We really appreciate your request in recent e-mail. We already have corrected, checked, and confirmed the manuscript. Therefore, we send you the final approved manuscript along with duly filled author proof form through the attachment file in this e-mail.

Thank you for your attention and guidance

Best Regards,

Desdiani Desdiani, MD, PhD

Pada Selasa, 6 Juni 2023 pukul 00.03.01 WIB, Editor WJBPR <editor-wjbpr@zealjournals.com> menulis:

Dear Author,
Greetings for the day...

We are grateful for your association with us. Please find herewith attached final edited version (as a word file) of your manuscript (ref no. WJBPR-2023-0051) entitled *"Diclofenac sodium and Allopurinol induced Stevens-Johnson Syndrome in pulmonary tuberculosis patients receiving intensive phase first-line antituberculosis drugs"* which is accepted for publication in World Journal of Biological and Pharmaceutical Research (WJBPR).

Download Author proof copy of your manuscript:

<https://zealjournals.com/wjbpr/sites/default/files/Attached%20Files/WJBPR...>

Download Author query form:

<https://zealjournals.com/wjbpr/content/downloads>

Special Note:

- Provide the name(s) of authors as First Name (Given name)-Middle Name- Last name (Family name/Surname) for each author and check that all names are accurately spelled. It is important from indexing purpose.
- Use degree Celsius unit "°C" instead of superscript zero. Ex. "390 C" should be written as "39 °C".
- Author should provide figures as author predict in manuscript (Highlighted text).
- Author should provide an appropriate conclusion to the article. Write conclusion as single para. Conclusion should be concise, informative and can be started with summarizing outcome of the study in 1-2 sentence and ended with one line stating: how this study will benefit to the society and way forward.
- Provide appropriate statement of ethical approval in the manuscript.

- While writing reference citation in the main text at the end of sentence, author has put full stop before square bracket "[1]". It should be corrected by writing full stop after square bracket as "[1]". Check and correct throughout the manuscript.
- Ensure that, all the references appearing in the text should be enlisted at the end in reference section and vice versa.

Without this we will not able to process your manuscript further.

We hereby request you that,

1. Read the proof at least thrice, note the errors and make necessary corrections (in blue colored text) to make the manuscript error free.
2. Do not change the format of the word file, just check the spelling and other errors in the attached text part.
3. Use this proof for checking the typesetting, editing, completeness and correctness of the text, tables and figures.
4. Significant changes to the article will only be considered at this stage with permission from the Editor.
5. Make sure that you send final approved copy of article proof along with duly filled Author proof form within 3 days after receipt of this e-mail.

6. Your manuscript will not be further processed for publication until and unless we receive your final approved article proof and Author query form.


7. It is responsibility to author to check each and every word and spelling including italic and normal formatting of specific names. No changes will be accepted after this. If any changes are expected after publication of manuscript, author will have to pay charges accordingly.


We would appreciate to receive your corrected proof as a word file by e-mail within stipulated time period so that we can process your article quickly and efficiently.

Thank you for submitting your work to this journal.

If you need more information, please do not hesitate to contact us.

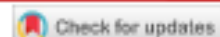With Best Regards,
Managing Editor
World Journal of Biological and Pharmaceutical Research (WJBPR)
editor-wjbr@zesjournals.com

 WJBPR-2023-0051 Article Proof.docx
6.9MB

 WJBPR-Authors queries for galley proof form.docx
68.7kB



(CASE REPORT)



Diclofenac sodium and Allopurinol induced Stevens Johnson Syndrome in pulmonary tuberculosis patients receiving intensive phase first-line antituberculosis drugs

Desdiani Desdiani*

Department of Pulmonology and Respiratory Medicine, Faculty of Medicine, Sultan Ageng Tirtayasa University, Serang, Banten, Indonesia.

World Journal of Biological and Pharmaceutical Research, 2023, XX(XX), XXX-XXX

Publication history: Received on 23 April 2023; revised on 02 June 2023; accepted on 05 June 2023

Article DOI: xxx

Abstract

One of the life-threatening multi-organ emergency conditions is Stevens-Johnson Syndrome (SJS). Although this is a rare disease and manifests as drug reactions, this condition can cause death. We present a case of a 63-year-old male with Diclofenac sodium and Allopurinol Induced Stevens Johnson Syndrome in pulmonary tuberculosis patients receiving intensive phase first-line antituberculosis drugs. The patient was undergoing outpatient TB treatment at the end of the first month. The patient comes to the emergency department of the hospital because of shortness of breath, fever, blistered skin, nasal and oral mucosa, cracks and wounds, visible pus, red eyes accompanied by erythematous rash all over the body after previously taking diclofenac sodium and allopurinol given by the doctor because felt joint pain all over body and uric acid increased. On physical examination of the lungs, crackles and wheezing were heard in both lung fields. The chest radiograph shows infiltrates in both lung fields. Laboratory results showed leukocytosis and the results of other blood laboratory tests were still within normal limits. Patient diagnosed Stevens-Johnson Syndrome based on clinical, laboratory, and radiology examination results. The patient was given treatments using nasal cannula oxygen of 5 litres/minute, intravenous fluid dehydration D5% : NaCl 0.9%, ceftriaxone injection, gentamicin injection, dexamethasone injection, cetirizine ranitidine injection, compresses with 0.9% NaCl liquid, 2.5% hydrocortisone ointment. The patient was treated in the Intensive Care Unit for 8 days. The patient had no history of previous drug allergies. In this case, the likelihood of Diclofenac sodium and Allopurinol Induced Stevens Johnson Syndrome in pulmonary tuberculosis patients receiving intensive phase first-line antituberculosis drugs, needs to be a concerned, as well as the importance of evaluation and strict follow-up to prevent Stevens Johnson Syndrome disease.

Keywords: Stevens Johnson Syndrome; Diclofenac sodium; Allopurinol; Antituberculosis drug

1. Introduction

Steven Johnson Syndrome is a rare vesiculo bullous disease characterized by acute skin eruption involving the skin and mucous membranes. This hypersensitivity reaction characterized by hyperpigmentation, skin rashes, target skin lesions involving blistering, erosion over face, trunk and limbs. Some studies reveal the incidence of SJS to be around 1.2-6 patients per 1 million per year. Some studies show that there are more men experiencing SJS [1]. More than 100 types of drugs have been reported to have potential cause SJS [2-4]. SJS patients have a high mortality rate. Main therapy SJS patients are supportive treatment and other treatment options.

Diclofenac sodium is a type of nonsteroidal anti-inflammatory drug (NSAID) which is most widely used as an analgesic drug. Several studies have revealed cases of mucocutaneous drug reactions secondary to NSAID treatment [5]. Allopurinol is the first-line therapy for gout but carries the risk of serious side effects. Stevens-Johnson syndrome (SJS) is one of the causes of severe cutaneous adverse reactions that can be life-threatening. The degree of severity of the disease is based on the extent of the skin affected. Several mechanisms related to SJS have been formulated. One of the

* Corresponding author: Desdiani Desdiani

mechanisms is the formation of haptened products produced by the combination of allopurinol with self peptide which is mediated by the activation of specific T cell antigens [6].

Many studies revealed the effect of anti-tuberculosis drugs on the incidence of drug-induced hepatitis, influenza-like diseases, arthralgia, and other skin reactions, which in severe forms are mediated by immunological processes, namely Stevens-Johnson syndrome (SJS), toxic epidermal necrolysis (TEN), drug reactions, with eosinophilia and systemic symptoms. Although all anti-tuberculosis drugs carry the risk of inducing Stevens-Johnson syndrome, rifampicin is most commonly associated with its occurrence [7].

2. Case

A 63-years-old male was admitted to the emergency unit of the hospital with shortness of breath, the skin blisters, the nose and mouth mucosa looks broken and sore, red nodules with pus accompanied by red rashes all over the body (Figure A-D). The patient is undergoing intensive phase TB treatment at the end of the first month. The patient had complained of itching since the first week of taking TB medication and it got better after taking cetirizine. The patient then took diclofenac sodium and allopurinol given by the doctor because he felt joint pain all over his body and increased uric acid. The patient still appeared conscious but weak and had a fever of 39°C. On physical examination of the lungs, crackles and wheezing were heard in both lung fields. The chest radiograph showed infiltrates in both lung fields. Laboratory results showed leukocytes 16,800cells/ μ and eosinophils 7%. Patients diagnosed with Diclofenac sodium and Allopurinol induced Stevens_Johnson Syndrome in pulmonary tuberculosis patients receiving intensive phase first-line antituberculosis drugbased on clinical, laboratory, and radiology examination results. The patient was given treatments using a nasal canule oxygen of 5 litre/minute, intravenous fluid dehydration D5% : NaCl 0.9% with a ratio of 3 : 1. The patient was also given treatments with ceftriaxone injection, gentamicin injection, dexamethasone injection, cetirizine ranitidine injection, compress 0.9% NaCl liquid 2 x 15 minutes on chafed lips, eyes and genitals, orabase 2 x daily, 2.5% hydrocortisone ointment 2 x daily for boils. The patient was treated in the Intensive Care Unit for 8 days. Day 9 the patient's condition improved and the wound began to dry. The patient was transferred to the inpatient room, and 3 days later was scheduled to be discharged. The patient has no previous history of drug allergies and has no comorbidities in his medical history (eg hypertension, diabetes mellitus, autoimmune disease, or malignancy). In this case, the likelihood of Diclofenac sodium and Allopurinol induced Stevens_Johnson Syndrome in pulmonary tuberculosis patients receiving intensive phase first-line antituberculosis drugs, needs to be concerned, as well as the importance of evaluation and strict follow-up to prevent Stevens Johnson Syndrome disease.

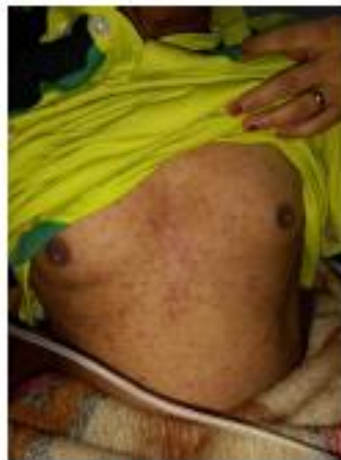

Figure A Patient's skin blisters



Figure B Patient's nose looks broken and sore

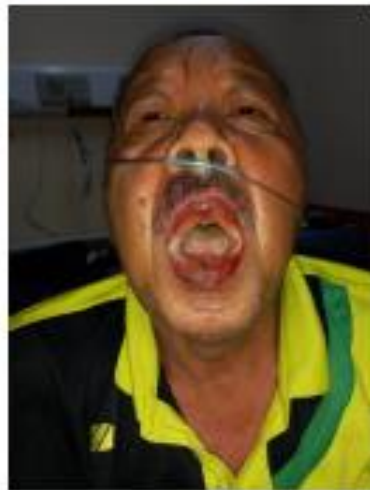

Figure C Crack and wound in Patient's nasal and oral mucosa

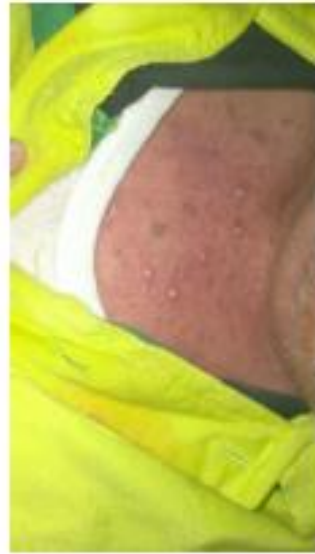

Figure D Red nodules with pus accompanied by red rashes all over the patient's body

3. Discussion

Stevens Johnson syndrome is a severe systemic disorder that has the potential to cause severe morbidity and death. SJS is a rare vesiculobullous disease characterized by acute skin eruptions involving the skin and mucous membranes. This is a type 4 hypersensitivity reaction with severe skin symptoms and is often accompanied by complications to several organs such as the liver, kidneys and lungs. The area of skin involved in Stevens Johnson Syndrome and toxic epidermal necrosis is divided as the degree of epidermal detachment of less than 10% of the body surface is called SJS, 10-30% is considered a mixture of SJS and toxic epidermal necrosis, >30% is considered toxic epidermal necrosis. The most common causes of SJS are drugs, which account for 80% of all cases of SJS, namely NSAIDs, allopurinol, carbamazepine, phenobarbital, phenytoin, valproic acid. SJS associated with NSAIDs is relatively rare. A study of 135 cases of skin reactions secondary to NSAID use showed that the oxicam class and its derivatives caused SJS the most compared to other types of NSAIDs [8,9].

The exact pathogenesis of SJS remains to be further investigated, however, the mechanisms of apoptosis including the involvement of tumor necrosis factor, cytotoxic T cells- α , Fas (CD 95) and Fas ligand interactions are thought to be associated with this disease. The pathobiology of SJS involves specific immune reactions, specific alleles of human leukocyte antigen (HLA) to certain drug populations in the activation of cytotoxic T lymphocytes and natural killer cells. A variety of cytotoxic and immunological signals, launched to mediate disseminated keratinocyte death and epidermal shedding in SJS. If this condition is not treated it can cause excruciating pain, fluid loss, massive protein loss, bleeding, evaporative heat loss with hypothermia and infection [9,10]. In this case, the patient appeared shortness of breath, fever, skin full of red rashes, pus nodules, blisters, sores especially on the oral and nasal mucosa. This condition was experienced after the patient who was undergoing TB therapy for the first month, took diclofenac sodium and allopurinol drugs.

The characteristic pattern of SJS is extensive necrotic keratinocytes or necrosis that causes the thickened epidermis. Vacuolized hemorrhages to subepidermal blisters are found on the basement membrane. Superficial lymphohistocytic infiltrates, often perivascular, may be seen in the upper dermis. While varying numbers of eosinophils were observed in tissue infiltrates on biopsy with Erythema multiforme major, Stevens Johnson syndrome and toxic epidermal necrosis. Another study revealed less epidermal necrosis, more dermal inflammation and exocytosis in erythema multiform major compared to Stevens Johnson syndrome [11]. In this patient, skin blisters appeared, laboratory results of leukocytosis and eosinophilia.

The success of therapy is largely determined by early detection of disease, discontinuation of drugs suspected as the cause of SJS and intensive and supportive care in a hospital or Intensive Care Unit that is fully equipped. Several drug agents that are anti-inflammatory or immunosuppressive have been considered and tried as alternative therapeutic options, but there is no single drug that is effective and proven from clinical trials. The therapy given to this patient was D5% and NaCl 0.9% Infusion, antibiotics, steroids, anti-inflammatory, anti-histamine, topical ointments and compresses [11].

4. Conclusion

We reported one case with Diclofenac sodium and Allopurinol induced Stevens Johnson Syndrome in pulmonary tuberculosis patients receiving intensive phase first-line antituberculosis drugs. The likelihood of Diclofenac sodium and Allopurinol induced Stevens Johnson Syndrome in Pulmonary Tuberculosis patients, it is necessary to pay attention, especially to drugs taken by patients other than anti-tuberculosis drugs, especially the NSAID class, which are taken together with the consumption of tuberculosis drugs. Although all antituberculosis drugs carry a risk of skin eruptions and SJS, rifampicin is most commonly associated with allergic reactions and SJS may occur.

Compliance with ethical standards

Acknowledgments

The authors express gratitude to the staff of Bhayangkara Brimoh Hospital who have contributed in providing medical data and records as well as all our patient who were involved in this report.

Statement of ethical approval

The present research work does not contain any studies performed on animals/humans subjects by any of the authors.

Statement of informed consent

Written informed consent for the publication of this study was obtained from the patient's family. A copy of the consent form is available upon request.

References

- [1] Sateesh Kumar Reddy K, Shanmuga Kumar SD, Vijay Raghavendra NC, Sudheer Kumar K. A Case Report on Diclofenac Induced Stevens Johnson Syndrome. *J Basic Clin Pharma* 2018, 9(2): 109-110
- [2] Ward KE, Archambault R, Mersfelder TL. Severe adverse skin reactions to nonsteroidal antiinflammatory drugs: A review of the literature. *Am J Health Syst Pharm* 2010, 67(3):206-213. DOI: <https://doi.org/10.2146/ajhp080603>.
- [3] Morelli MS, O'Brien FX. Stevens-Johnson syndrome and cholestatic hepatitis. *Dig Dis Sci* 2001, 46(11):2385-8. DOI: <https://doi.org/10.1023/A:1012351231143>.
- [4] Roujeau JC, Kelly JP, Naldi L, et al. Medication use and the risk of Stevens-Johnson syndrome or toxic epidermal necrolysis. *N Engl J Med* 1995, 333(24):1600-1607. DOI: <https://doi.org/10.1056/NEJM199512143332404>.
- [5] Gupta SS, Sabharwal N, Patti R, Kupfer Y. Allopurinol-induced stevens-sohnson syndrome. *American Journal of Medical Science* 2019, 357(4): 348-351
- [6] Jin HJ, Kang DY, Nam YH, Ye YM, Koh YI, Hur GY, et. al. Severe cutaneous adverse reactions to anti-tuberculosis drugs in korea patients. *Allergy Asthma Immunol Res* 2021, 13(2): 245-255
- [7] Stern RS, Biogly M. An expanded profile of cutaneous reactions to NSAIDs, Reporting to a specialty based system for spontaneous reporting of ADRs. *JAMA* 1984, 21:252-65.
- [8] Saha K. Toxic epidermal necrolysis, current concept in pathogenesis and treatment. *India Dermatol Venereal Leprol* 2000, 66:7-10.
- [9] Chism S, Chung CH. Update on pathobiology in SJS and TEN. *Dermatologic sinica* 2013, 3:175-180.
- [10] Mockenhaupt M. The current understanding of SJS and TEN. *Expert review of Clinical Immunology* 2014, 7:803-15.

Author Queries



World Journal of Biological and Pharmaceutical Research (WJBPR)

Author Queries

Title of the Manuscript: Diclofenac sodium and Allopurinol induced Stevens Johnson Syndrome in pulmonary tuberculosis patients receiving intensive phase first-line antituberculosis drugs

Queries	Details Required	Author's Response
AQ1	Please check and confirm the type of the article is correct.	Checked and Confirmed
AQ2	Please check and confirm the title of the article is correct.	Checked and Confirmed
AQ3	Please check and confirm the spellings of all the author names, their sequence, affiliations, corresponding author is correctly indicated and details (e-mail, phone)	Checked and Confirmed
AQ4	Please check and confirm that all the keywords given by author are mentioned and correctly spelled.	Checked and Confirmed
AQ5	Please check whether all heading and subheading levels are okay.	Checked and Confirmed
AQ6	Please check and confirm that all spellings and grammar in the entire text are correctly used.	Checked and Confirmed
AQ7	Please check and confirm that all the punctuation marks are appropriately given.	Checked and Confirmed
AQ8	Please check and confirm that all the scientific nomenclature, units, symbols and abbreviations are correctly presented	Checked and Corrected
AQ9	Please check and confirm that all Tables and Figures are included in the manuscript.	Checked and Corrected
AQ10	Please check and confirm that all the caption of Tables and Figures are correctly presented.	Checked and Corrected
AQ11	Please check and confirm that all footnotes of tables are okay.	Checked and Confirmed
AQ12	Please check and confirm that all the formulae (if present) are correctly presented.	Checked and Confirmed
AQ13	Please check and confirm that statements about 'Compliance with Ethical Standards' and correctly presented before reference section. These include (i) Acknowledgement (compulsory), (ii) Disclosure of conflict of interest (compulsory), (iii) Statement of ethical approval (if any) and (iv) Informed consent (if any).	Checked and Corrected
AQ14	Please check and confirm that all the References cited in the text are given in the reference list and vice versa. Please provide details in the list or delete the citation from the text if applicable	Checked and Confirmed
AQ15	Please check, whether you want to display author biography or not. If yes then provide Author biography in short (4-5 lines) with passport size photograph at the end of manuscript.	Checked and Confirmed



**World Journal of Biological and Pharmaceutical Research
(WJBPR)**

Author should check all above queries. If okay then mention "Checked and Confirmed" in the Author's Response column; otherwise, do the necessary changes in the galley proof (in blue color text) and mention "Checked and Corrected" in the Author's Response column.

Article Published

8/11/23, 1:05 PM

Yahoo Mail - Your Manuscript has been published in of World Journal of Biological and Pharmaceutical Research (WJBPR).

Your Manuscript has been published in of World Journal of Biological and Pharmaceutical Research (WJBPR).

Dari: Editor WJBPR (editor-wjpr@zealjournals.com)

Kepada: desdiani@gmail.com

Tanggal: Kamis, 8 Juni 2023 pukul 22.56 WIB

Dear Author,
Greetings for the day...

We are pleased to inform you that your manuscript entitled ***"Diclofenac sodium and Allopurinol induced Stevens_Johnson Syndrome in pulmonary tuberculosis patients receiving intensive phase first-line antituberculosis drugs"*** has been published in of World Journal of Biological and Pharmaceutical Research (WJBPR).

You can view or download your article from the below links

<https://zealjournals.com/wjpr/content/diclofenac-sodium-and-allopurinol...>

<https://zealjournals.com/wjpr/sites/default/files/WJBPR-2023-0051.pdf>

Crossref DOI and CrossMark metadata information will be updated very soon. We will inform you regarding this.

I hope you are happy with our services and have good experience while publishing with us. We will be happy to review and publish your next manuscript in this journal. **You may also consider our other allied journals...**

World Journal of Advanced Science and Technology
World Journal of Advanced Pharmaceutical and Medical Research
World Journal of Advanced Pharmaceutical and Life Sciences
World Journal of Chemical and Pharmaceutical Sciences

Visit these journals at: <https://zealjournals.com/content/our-journals>

We will look forward to the submission of your next manuscripts.

With Best Regards,
Managing Editor
World Journal of Biological and Pharmaceutical Research (WJBPR)
editor-wjpr@zealjournals.com

Quick Links

[Submit Article](#)

[Author's Guidelines](#)

[Past Issues](#)

[Publication Certificate](#)

Journal Indexing



Diclofenac sodium and Allopurinol induced Stevens Johnson Syndrome in pulmonary tuberculosis patients receiving intensive phase first-line antituberculosis drugs

Desdiani Desdiani *

Department of Pulmonology and Respiratory Medicine, Faculty of Medicine, Sultan Ageng Tirtayasa University, Serang, Banten, Indonesia.

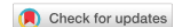Research Article

World Journal of Biological and Pharmaceutical Research, 2023, 04(02), 010–013.

Article DOI: 10.53346/wjbpr.2023.4.2.0051

DOI url: <https://doi.org/10.53346/wjbpr.2023.4.2.0051>

Publication history: Received on 23 April 2023; revised on 02 June 2023; accepted on 05 June 2023



Abstract:

One of the life-threatening multi-organ emergency conditions is Stevens-Johnson Syndrome (SJS). Although this is a rare disease and manifests as drug reactions, this condition can cause death. We present a case of a 63-year-old male with Diclofenac sodium and Allopurinol induced Stevens-Johnson Syndrome in pulmonary tuberculosis patients receiving intensive phase first-line antituberculosis drugs. The patient was undergoing outpatient TB treatment at the end of the first month. The patient comes to the emergency department of the hospital because of shortness of breath, fever, blistered skin, nasal and oral mucosa, cracks and wounds, visible pus, red eyes accompanied by erythematous rash all over the body after previously taking diclofenac sodium and allopurinol given by the doctor because felt joint pain all over body and uric acid increased. On physical examination of the lungs, crackles and wheezing were heard in both lung fields. The chest radiograph shows infiltrates in both lung fields. Laboratory results showed leukocytosis and the results of other blood laboratory tests were still within normal limits. Patient diagnosed Stevens-Johnson Syndrome based on clinical, laboratory, and radiology examination results. The patient was given treatments using nasal canule oxygen of 5 litres/minute, intravenous fluid dehydration D5% : NaCl 0.9%, ceftriaxone injection, gentamicin injection, dexamethasone injection, cetirizine ranitidine injection, compresses with 0.9% NaCl liquid, 2.5% hydrocortisone ointment. The patient was treated in the Intensive Care Unit for 8 days. The patient had no history of previous drug allergies. In this case, the likelihood of Diclofenac sodium and Allopurinol induced Stevens-Johnson Syndrome in pulmonary tuberculosis patients receiving intensive phase first-line antituberculosis drugs, needs to be a concern, as well as the importance of evaluation and strict follow-up to prevent Stevens Johnson Syndrome disease.

Keywords: Stevens Johnson Syndrome; Diclofenac sodium; Allopurinol; Antituberculosis drug

Link : <https://zealjournals.com/wjbpr/content/diclofenac-sodium-and-allopurinol-induced-stevens-johnson-syndrome-pulmonary-tuberculosis>