

Case Report: Delayed treatment of tuberculosis of the elbow joint [version 2; peer review: 2 approved]

by Desdiani Desdiani, Hidayat Rizal, Anindita Basuki, Fadilah Fadilah

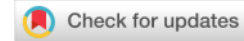Submission date: 17-Apr-2023 01:26PM (UTC+0800)

Submission ID: 2066885789

File name: f1000research-10-133791.pdf (1.18M)

Word count: 6022

Character count: 32948



CASE REPORT

REVISED Case Report: Delayed treatment of tuberculosis of the elbow joint [version 2; peer review: 2 approved]

Desdiani Desdiani ^{1,2}, Hidayat Rizal³, Anindita Basuki⁴, Fadilah Fadilah ⁵

¹Faculty of Medicine, Universitas Sultan Ageng Tirtayasa, Cilegon, 42434, Indonesia

²Department of Pulmonology and Respiratory Medicine, Bhayangkara Brimob Hospital, Depok, 16451, Indonesia

³Department of Orthopaedic, Bhayangkara Brimob Hospital, Depok, 16451, Indonesia

⁴Department of Radiology, Bhayangkara Brimob Hospital, Depok, 16451, Indonesia

⁵Department of Medical Chemistry, Faculty of Medicine, Universitas Indonesia, Jakarta, 10430, Indonesia

V2 First published: 18 Jun 2021, 10:486
<https://doi.org/10.12688/f1000research.53488.1>
 Latest published: 13 May 2022, 10:486
<https://doi.org/10.12688/f1000research.53488.2>

Abstract

Extrapulmonary tuberculosis (TB) is known to occur in the musculoskeletal system, including the elbow joints. These cases are rarely found because the signs and symptoms are not specific to extrapulmonary TB or other diseases. We report a case of a 24-year-old male, who complained about pain in his left elbow and noticed swelling. Initially, he complained about pain all over his left arm, after several reflexology massages to alleviate his toothache. However, instead of seeking medical treatment, he visited a traditional massage therapist every week without improvement in his left arm pain including his left elbow for almost one year. Examination showed skin perforation with discharge. He also had fever during the first few days when the elbow became swollen. Weight loss and a decreased appetite were also noticed by the patient. The patient went to the orthopedic department and underwent surgery. Radiological examination indicated bone erosion on the left humerus and radius, while posteroanterior chest X-ray did not show any abnormality. Histopathological examinations from biopsy and fluid aspiration showed granulomas and Langhans cells. *Mycobacterium tuberculosis* was found on acid-fast bacteria smear and culture. The patient was administered multidrug tuberculosis therapy, which consisted of two months of an intensive phase and seven months of a continuation phase, in accordance with the World Health Organization's guidelines for extrapulmonary tuberculosis treatment. He has currently undergone the continuation phase of the treatment and his condition has improved. Early detection of tuberculosis of the elbow can prevent damage to joint structure and impairment of joint function.

Keywords

Elbow, Arthritis, Tuberculosis, Delayed treatment

Open Peer Review

Approval Status

	1	2
version 2		
(revision)		
13 May 2022	view	view
version 1		
18 Jun 2021	view	view

1. **Musofa Rusli** , Airlangga University, Surabaya, Indonesia

2. **Yunita Arliny** , Universitas Syiah Kuala, Banda Aceh, Indonesia

Any reports and responses or comments on the article can be found at the end of the article.

Corresponding author: Desdiani Desdiani (desdiani@gmail.com)

Author roles: **Desdiani D:** Conceptualization, Data Curation, Funding Acquisition, Investigation, Supervision, Validation, Writing – Original Draft Preparation, Writing – Review & Editing; **Rizal H:** Conceptualization, Supervision, Validation; **Basuki A:** Conceptualization, Supervision, Validation; **Fadilah F:** Formal Analysis, Investigation, Supervision, Visualization, Writing – Review & Editing

Competing interests: No competing interests were disclosed.

Grant information: The author(s) declared that no grants were involved in supporting this work.

Copyright: © 2022 Desdiani D *et al.* This is an open access article distributed under the terms of the [Creative Commons Attribution License](#), which permits unrestricted use, distribution, and reproduction in any medium, provided the original work is properly cited.

How to cite this article: Desdiani D, Rizal H, Basuki A and Fadilah F. **Case Report: Delayed treatment of tuberculosis of the elbow joint [version 2; peer review: 2 approved]** F1000Research 2022, 10:486 <https://doi.org/10.12688/f1000research.53488.2>

First published: 18 Jun 2021, 10:486 <https://doi.org/10.12688/f1000research.53488.1>

REVISED Amendments from Version 1

We have added a few sentences such as “including his left elbow” in the abstract section, epidemiology (age, gender) in the introduction section, the patient was suspected of TB of the elbow joint, the patient was subsequently diagnosed with TB of the elbow joint, the result of the AFB examination based on WHO-IUATLD scales in case report section and pathogenesis of tuberculous elbow in a discussion section.

Any further responses from the reviewers can be found at the end of the article

Abbreviations

AFB: acid fast-bacteria
 AP: anteroposterior
 CKD: chronic kidney disease
 CT: computed tomography
 ESR: erythrocyte sedimentation rate
 HIV: human immunodeficiency virus
 PA: posteroanterior
 TB: tuberculosis
 WHO: World Health Organization

Introduction

Extrapulmonary tuberculosis (TB) is known to occur in joints with a percentage of approximately 1-3% of all TB cases of which 2-5% are rare cases that occur in the elbow joints.¹ TB is an endemic disease with the total number of cases approximating 845,000 in Indonesia.² Males and females have identical rates of infection with *Mycobacterium tuberculosis* until adolescence, following which males have a greater rate. For all ages, male rates became higher than female rates. The average age of tuberculous vertebral osteomyelitis patients is 45–60 years old. Nonetheless, some research show a bimodal age distribution, with two peaks, one between 20 and 30 years old, linked to immigration and/or HIV infection almost 60% of cases in one study, and the other between 60 and 70 years old.³ Elbow dysfunction is the result of the progressive of erosion and destruction of bone and joint, therefore early diagnosis and treatment are needed to prevent this outcome. Diagnosis is quite challenging and often late due to non-specific symptoms.⁴ Joint TB is rarely detected because joint pain is not commonly considered to be a symptom of joint TB, especially if there are no respiratory complaints. Thus, diagnosis and treatment are often delayed. Here, we report a rare case of a patient with TB of the elbow joint, who received delayed treatment because he chose to undergo traditional treatment with massage therapy.

Case report

A 24-year-old Indonesian male who worked in an internet rental shop came to the orthopedic department of Bhayangkara Brimob hospital (Depok, Indonesia) with left arm pain and left elbow joint swelling. Physical examination revealed skin perforation with yellowish discharge on the left elbow. The patient experienced fever on the first few days as the left elbow became swollen, weight loss, and a decreased appetite, but no respiratory complaints.

Chronologically, one year prior to coming to the hospital, the patient noticed another pain in his left arm both in the upper and lower arm. He then chose to undergo regular traditional massage therapy every week for almost one year instead of seeking for medical treatments. At the first hospital visit, the elbow pain had gotten more severe and became swollen. Within a month, discharge emerged from a small skin perforation located on the inner side of the left elbow. The patient finally went to the orthopedic department and underwent surgery. The patient had a history of undergoing reflexology massages on between the fingers of his left hand to alleviate his toothache.

Upon physical examination, the left elbow joint appeared swollen and discharge was exuding from the perforated skin, as depicted in [Figure 1](#). The patient could not lift his left arm because it was be painful. Flexion and extension were also difficult due to the severity of the pain. The patient’s social environment has a culture of seek help from local traditional massage therapist who is known to be uncertified for various health problems, and instead of recovering, the patient showed symptoms that are worsening.

Laboratory examination revealed a leukocyte count of 15,000 (normal range: 5000-10,000 cells/ μ l), erythrocyte sedimentation rate (ESR) of 40 mm/hour (normal range: 0-10 mm/hour), eosinophils 9% (normal range: 1-3%), and monocytes 10% (normal range: 2-6%). Radiological examination by posteroanterior (PA) chest X-ray did not show any abnormality ([Figure 2](#)), anteroposterior (AP) and lateral projection of the left elbow joint radiographs showed erosion of

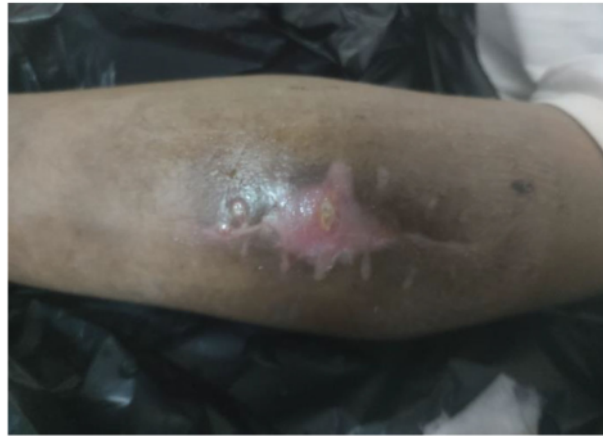

Figure 1. Left elbow joint appeared swollen, discharge was exuding from the perforated skin (photo after surgery).

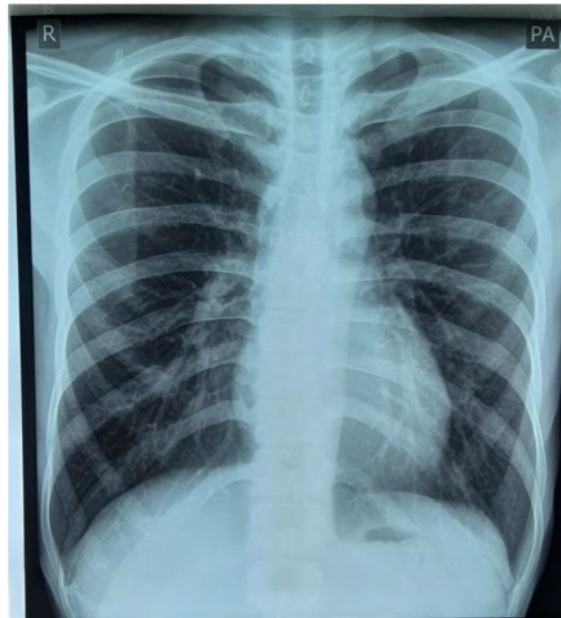


Figure 2. Radiological examination by posteroanterior chest X-ray did not show any abnormality.

the distal cortex of the humerus and radial bone, destruction of the distal cortex, and swelling of the soft tissue of the left elbow area (Figure 3).

The patient was suspected with TB of the elbow joint. He then underwent left elbow arthrotomy and synovial fluid aspiration. The surgery was performed with the patient supine under general anesthesia. Incisions were made layer by layer on the posterior region of *cubiti sinistra*. White granulation tissue and thick yellow intra- and extra-articular pus were evacuated. Histopathological examination was also performed. The wound was irrigated with 2 L of 0.9% NaCl and hecting was performed layer by layer subsequently. Specimens were collected and sent for microbiological and pathological analyses. The result of the AFB examination was based on types of grading scale by the World Health Organization and the International Union against Tuberculosis and Lung Disease (WHO-IUATLD) was 2+. Tissue

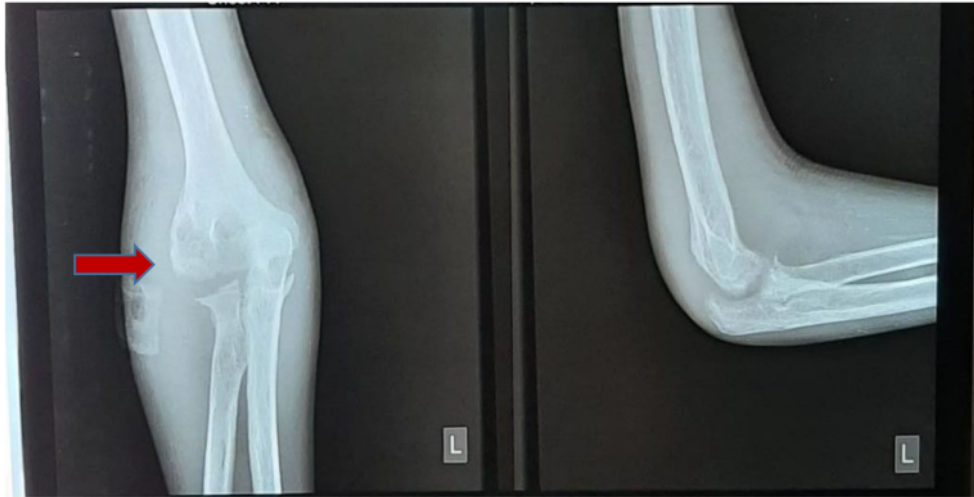

Figure 3. Anteroposterior and lateral projection of the left elbow joint radiographs showed erosion of the distal cortex of the humerus and radial bone, destruction of the distal cortex, and swelling of the soft tissue of the left elbow area (February 2021).

culture was found to be positive. Histopathological examination showed granulomatous inflammation, swollen connective tissues containing epithelioid tubercle nests with necrotization, and datia Langhans cells (Figure 4). The results were consistent with TB. Furthermore, the anti-human immunodeficiency virus (HIV) test was negative. The patient was subsequently diagnosed with TB of the elbow joint.

² The patient was given a standard first-line oral regimen of extrapulmonary TB treatment; an intensive phase for two months with rifampicin 450 mg once dai² isoniazid 300 mg once daily, pyrazinamide 1000 mg once daily, and ethambutol 1000 mg once daily (2HRZE) and seven months of a continuation phase with rifampicin 450 mg once daily and isoniazid 300 mg once daily (7HR). The patient had been undergoing continuation phase of the treatment and his condition showing improvements, including decreased pain, increased appetite, and weight gain. However, flexion and

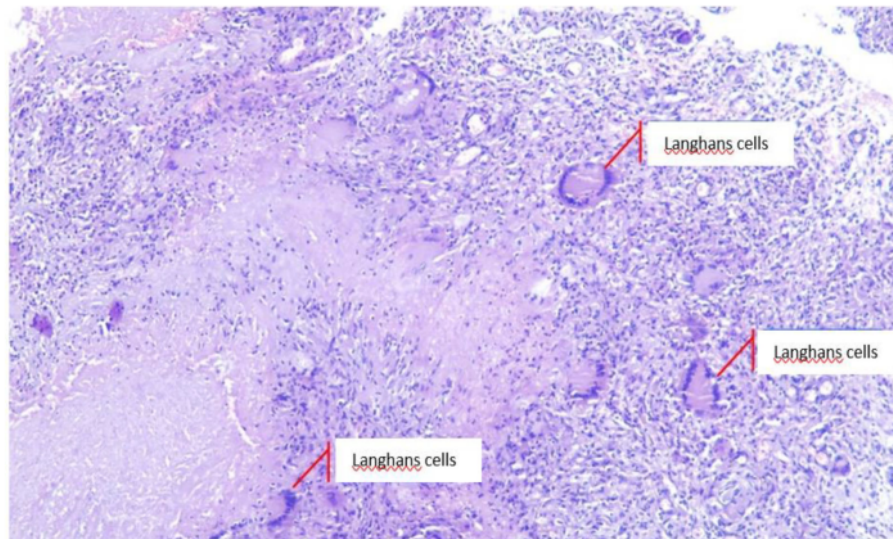


Figure 4. Granulomatous inflammation, swollen connective tissues containing epithelioid tubercle nests with necrotization, and datia Langhans cells.

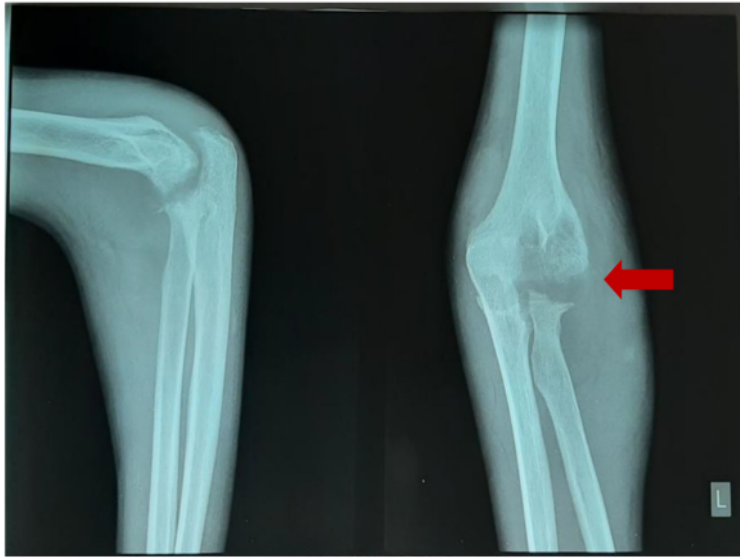


Figure 5. Minimal improvement, AP and lateral projection of the left elbow joint radiographs showed erosion of the distal cortex of the humerus and radial bone, destruction of the distal cortex, and swelling of the soft tissue of the left elbow area (March 2021).

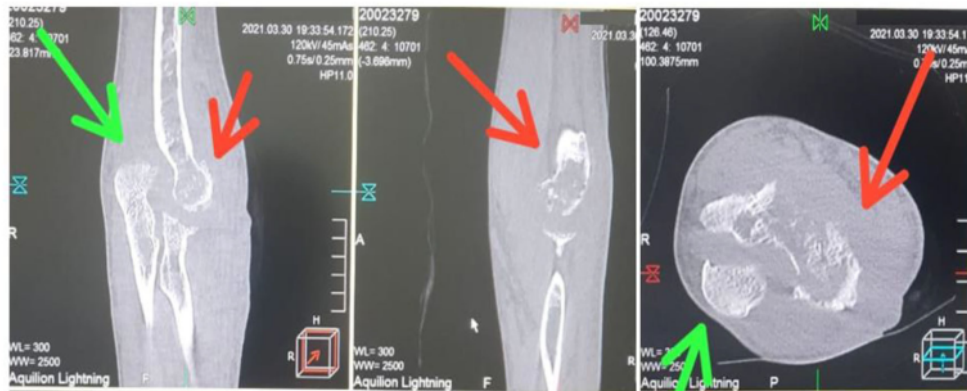


Figure 6. Computed tomography scan shows destruction of the lateral epicondylus of the humeral bone and the processus olecranon of ulna bones (red arrows = humerus bones, green arrows = ulna bones). Picture was edited with photoshop CS4 version 11.0 to remove specific details of dates of patient care and patient's identity.

extension are restricted. The patient reported clinical improvement and discharge was decreased. Left elbow joint radiographs showed minimal improvement (Figure 5). Computed tomography (CT) scan results showed destruction of the lateral *epicondylus* of the humeral bone and the *processus olecranon* of ulna bones, after two months of the treatment (Figure 6).

Discussion

Musculoskeletal TB occurs in about 10% of all cases of extrapulmonary tuberculosis, which commonly affects weight-bearing joints such as spine (51%), pelvis (12%), hip and femur (10%), knee and tibia (10%). Reported cases of non-weight-bearing joints such as elbow joint TB are still relatively few, and the diagnosis still often to be neglected.¹

Reactivation of bacilli embedded in bone during the first mycobacteremia of primary infection causes tuberculous elbow and arthritis. The extensive vascular supply of the vertebra and growth plates of the long bones explains the bacillus'

preference for the spine and major joints. Musculoskeletal tuberculosis develops as a result of the bacilli being seeded in the bloodstream shortly after the initial pulmonary infection. Osteoarticular tuberculosis begins as osteomyelitis in the growth plates of bones, where the blood supply is strongest, and subsequently spreads locally into joint spaces. It can also spread through the lymphatic system; however this is a less usual occurrence. The stimulation of dormant lymphatic or blood stream areas of morbidity might cause infections in joints. In the long bones, tuberculosis begins in the epiphysis and progresses to the marrow, where it causes tubercle formation and trabeculae infection. The mycobacteria cause an inflammatory response in the synovium of the joint, which is followed by the production of granulation tissue. The granulation tissue pannus then starts to erode and degrade cartilage and finally bone, resulting in demineralization.⁵⁻⁷

Diagnosis of musculoskeletal TB requires the clinician's ability to pay attention to joint swelling and chronic pain, as well as their effects on joint function.⁵

Usually, respiratory and systemic symptoms are absent or only briefly present. In this report, only a history of fever was identified. Radiological examination of the lungs showed no abnormality. The complaints for joint TB are often non-specific, hence a late diagnosis.¹

The findings in this report are consistent with several previous studies. A study by Yazici *et al.* (2016) reported a TB of the elbow joint case in which there were no signs and symptoms of respiration. The results of chest radiographs were still within normal limits. The diagnosis was confirmed by AFB and histopathology examinations.⁸ Another study by Guan & Zeng (2021) reported osteoarticular TB with a picture of swelling and pain that was previously diagnosed as osteoarthritis. Although these cases are rare, they are difficult to diagnose and can cause pain and impaired function.⁹

Radiographic changes of the joints may suggest multiple osteolytic lesions and there may be erosions of the joints and swelling of the soft tissues.¹⁰ Unfortunately, this patient did not undergo a magnetic resonance imaging examination due to the limited available facilities. Definite diagnosis required synovial fluid aspiration. Microscopic examination and culture of fluid aspiration were very helpful, followed by histopathological results showing the caseous granuloma.¹¹ These non-specific sign and symptoms were often delay the diagnosed as skeletal TB, as reported in one study that shows the time lag from the onset of complaints until the diagnosis was confirmed as approximately 4-11 months. Additionally, some cases of skeletal TB occasionally showed negative results on AFB and culture.^{12,13}

Clinicians should not neglect to explore the history of exposure and factors that increase the risks of TB infection such as close contact with confirmed TB patients, immunocompromise (e.g. HIV infection), diabetes *mellitus*, and having comorbid diseases such as chronic kidney disease. Therefore, it is necessary to screen the patient for co-infectious diseases listed above. Other risk factors are old age, poor nutrition, and receiving immunosuppressive treatments.⁶ Regarding this case, the risk factors are not clear.

In summary, the significance of this case is the recognition of risk factors for skeletal TB and chronic symptoms, so that they can be treated properly. Early diagnosis and treatment can be achieved through with careful anamnesis that does not ignore the history of close contact with confirmed case TB patients, risk factors for TB infection, physical/clinical, radiological, and laboratory examinations. It is important for clinicians, especially those who work in an area endemic to suspect chronic joint pain whose clinical symptoms do not improve with conventional treatment as skeletal TB as the differential diagnosis. The specific AFB smear and culture tests are still important, although can occasionally show false negative results. Extrapulmonary TB can be deceptive because it does not always cause typical symptoms and pulmonary involvement. Prompt diagnosis and treatment are essential to prevent joint damage and impaired function.

Patient's perspectives

Left-arm and elbow pain, swelling, and immobility made me suffer. I knew that I had to go to the hospital for further treatment. However, I was afraid of surgery and at the suggestion of my family, I underwent traditional medicine with massage therapy for almost 1 year. I didn't expect that my illness would get worse and I had to have surgery immediately and take long-term medication. Now I feel better, my arm pain and swelling of my left elbow have decreased, even though I haven't been able to move my arm to its full potential.

Data availability

All data underlying the results are available as part of the article and no additional source data are required.

Consent

Written informed consent for publication of their clinical details and clinical images was obtained from the patient.

References

1. Thimmaiah VT, Deepashree: **Unusual presentation of tuberculosis of elbow joint: a case report.** *Res Rev: J Med Health Sci.* 2013; **2**(4): 17-20.
2. World Health Organization; **WHO. Global tuberculosis report [Internet].** *Who. int.* 2018 [cited 2021 Apr 1]. [Reference Source](#)
3. Holmes CB, Häusler H, Nunn P: **Review of sex differences in the epidemiology of tuberculosis.** *Int J Tuberc Lung Dis.* 1998; **2**(2): 96-104.
4. Broderick C, Hopkins S, Mack DJF, et al.: **Delays in the diagnosis and treatment of bone and joint tuberculosis in the United Kingdom.** *Bone Joint J.* 2018 Jan; **100-B**(1): 119-24. [10 Med Abstract](#) | [Publisher Full Text](#)
5. Pigrau-Serrallach C, Rodríguez-Pardo D: **Bone and joint tuberculosis.** *Eur Spine J.* 2012 Jun 19; **22**(S4): 556-66. [PubMed Abstract](#) | [Publisher Full Text](#) | [Free Full Text](#)
6. Mousa HA-L: **Bones and Joints Tuberculosis.** *Bahrain Med Bull.* 2007; **29**(1): 17-21.
7. Dhillon M, Goel A, Prabhakar S, et al.: **Tuberculosis of the elbow: A clinicoradiological analysis.** *In: Orthop.* 2012 Mar; **46**(2): 200. [17](#)
8. Yazici A, Kayan G, Yaylaci S, et al.: **Tuberculous arthritis of the elbow joint: A case report.** *Eur J Rheumatol.* 2016 Sep 26; **3**(3): 142-3. [PubMed Abstract](#) | [Publisher Full Text](#) | [Free Full Text](#)
9. Guan Y, Zeng Z: **Elbow arthroplasty complicated by Mycobacterium tuberculosis infection.** *Medicine.* 2021 Mar 5; **100**(9): e24376. [5 Med Abstract](#) | [Publisher Full Text](#) | [Free Full Text](#)
10. De Backer AI, Vanhoenacker FM, Sanghvi DA: **Imaging features of extraaxial musculoskeletal tuberculosis.** *Indian J Radiol Imaging.* 2009; **19**(3): 176-86. [PubMed Abstract](#) | [4 Publisher Full Text](#) | [Free Full Text](#)
11. Arathi N, Fayaz A, Huda N: **Osteoarticular tuberculosis-a three years retrospective study.** *J Clin Diagn Res.* 2013; **7**(10): 2189-92. [PubMed Abstract](#) | [Publisher Full Text](#) | [12 Full Text](#)
12. Held MFG, Hoppe S, Laubscher M, et al.: **Epidemiology of Musculoskeletal Tuberculosis in an Area with High Disease Prevalence.** *Asian Spine J.* 2017 Jun 30 [cited 2021 Apr 1]; **11**(3): 405-11. [9 Med Abstract](#) | [Publisher Full Text](#) | [Free Full Text](#)
13. Garg RK, Somvanshi DS: **Spinal tuberculosis: A review.** *J Spinal Cord Med.* 2011 Sep [cited 2021 Apr 1]; **34**(5): 440-54. [PubMed Abstract](#) | [Publisher Full Text](#) | [Free Full Text](#)

Open Peer Review

Current Peer Review Status:  

Version 2

Reviewer Report 15 June 2022

<https://doi.org/10.5256/f1000research.133791.r137727>

© 2022 Arliny Y. This is an open access peer review report distributed under the terms of the [Creative Commons Attribution License](#), which permits unrestricted use, distribution, and reproduction in any medium, provided the original work is properly cited.



Munita Arliny 

Department of Pulmonology and Respiratory Medicine, Faculty of Medicine, Universitas Syiah Kuala, Banda Aceh, Indonesia

Changes made in version 2 are good and appropriate.

Competing Interests: No competing interests were disclosed.

Reviewer Expertise: pulmonary infection

I confirm that I have read this submission and believe that I have an appropriate level of expertise to confirm that it is of an acceptable scientific standard.

Reviewer Report 06 June 2022

<https://doi.org/10.5256/f1000research.133791.r137728>

© 2022 Rusli M. This is an open access peer review report distributed under the terms of the [Creative Commons Attribution License](#), which permits unrestricted use, distribution, and reproduction in any medium, provided the original work is properly cited.



Musofa Rusli 

Department of Internal Medicine, Faculty of Medicine, Airlangga University, Surabaya, Indonesia

I have no further comments to make.

Competing Interests: No competing interests were disclosed.

Reviewer Expertise: Infectious disease

I confirm that I have read this submission and believe that I have an appropriate level of expertise to confirm that it is of an acceptable scientific standard.

Version 1

Reviewer Report 04 April 2022

<https://doi.org/10.5256/f1000research.56876.r127931>

© 2022 Arliny Y. This is an open access peer review report distributed under the terms of the [Creative Commons Attribution License](#), which permits unrestricted use, distribution, and reproduction in any medium, provided the original work is properly cited.



Arliny Y.

Department of Pulmonology and Respiratory Medicine, Faculty of Medicine, Universitas Syiah Kuala, Banda Aceh, Indonesia

1. Reflexology that is done for complaints of elbow pain or pain in other places? Because it is somewhat contrary to the statement of elbow pain and does not seem to be related to delayed therapy.
2. On photo session, it's better if you include a photo of the elbow before the operation.
3. The sentence "The patient was subsequently diagnosed with TB of the elbow joint" should be placed after the results of AFB and histopathological examinations are obtained. the sentence "diagnosed with TB of the elbow joint" should be replaced with suspected TB elbow joint.
4. Please complete the result of AFB examination (IULTD scale) and culture.
5. Has the patients examined of Gene Xpert MTB/RIF from the tissue? Please mention this.
6. Please add an explanation of the epidemiology of bone and joint TB (age, gender) and its pathogenesis.
7. Please explain the sentence "The specific AFB smear and culture tests are still important, although they can occasionally show false negative results.
8. Please mention the gold standard of diagnostics for bones or joint TB.

Is the background of the case's history and progression described in sufficient detail?

Partly

Are enough details provided of any physical examination and diagnostic tests, treatment given and outcomes?

Partly

Is sufficient discussion included of the importance of the findings and their relevance to future understanding of disease processes, diagnosis or treatment?

Partly

Is the case presented with sufficient detail to be useful for other practitioners?

Yes

Competing Interests: No competing interests were disclosed.

Reviewer Expertise: pulmonary infection

I confirm that I have read this submission and believe that I have an appropriate level of expertise to confirm that it is of an acceptable scientific standard, however I have significant reservations, as outlined above.

Author Response 05 May 2022

Desdiani Desdiani, Universitas Sultan Ageng Tirtayasa, Cilegon, Indonesia

Dear Dr. Yunita Arliny,

Thank you for allowing us the opportunity to submit a revised draft of the manuscript "Case Report: Delayed treatment of tuberculosis of the elbow joint" for publication in the F1000Research.

We appreciate the time and effort that you dedicated to providing feedback on our manuscript and are grateful for the insightful comments and valuable improvements to our paper. We have incorporated most of the suggestions made by the reviewers. Please see below, for a point-by-point response to the reviewers' comments and concerns:

Reflexology that is done for complaints of elbow pain or pain in other places? Because it is somewhat contrary to the statement of elbow pain and does not seem to be related to delayed therapy.

This patient complained about pain in his left elbow and noticed swelling. Initially, he complained about pain all over his left arm, after several reflexology massages to alleviate his toothache for almost 2 months. However, instead of seeking medical treatment, he visited a traditional massage therapist every week without improvement in his left arm pain including his left elbow for almost one year. At the first hospital visit, the elbow pain had gotten more severe and it became swollen. Discharge emerged from a small skin perforation located on the inner side of the left elbow. The patient finally went to the orthopedic department and underwent surgery.

On photo session, it's better if you include a photo of the elbow before the operation.

Initially, this patient came to the orthopedic clinic and was treated because of severe pain and swelling in the elbow of the left arm. Unfortunately, the orthopedic specialist did not think to take a photo, he was immediately treated and underwent laboratory and

radiological examinations, and then surgery was performed.

The sentence "The patient was subsequently diagnosed with TB of the elbow joint" should be placed after the results of AFB and histopathological examinations are obtained. the sentence "diagnosed with TB of the elbow joint" should be replaced with suspected TB elbow joint.

We agree and have updated.

Please complete the result of AFB examination (IULTD scale) and culture.

The result of the AFB examination is based on types of grading scale by the World Health Organization and the International Union against Tuberculosis and Lung Disease (WHO-IUATLD): **1-10 AFB per field, 2+**. Tissue culture was found to be positive.

Has the patients examined of Gene Xpert MTB/RIF from the tissue? Please mention this.

Initially, this patient came to the orthopedic clinic and was treated because of severe pain and swelling in the elbow of the left arm. Unfortunately, the orthopedic specialist did not think to take a photo, he was immediately treated and underwent laboratory and radiological examinations, and then surgery was performed. The source of the sample for histopathological examination was taken from white granulation tissue on the posterior region of cubiti sinistra. Histopathological examination showed granulomatous inflammation, swollen connective tissues containing epithelioid tubercle nests with necrotization, and data Langhans cells.

Please add an explanation of the epidemiology of bone and joint TB (age, gender) and its pathogenesis.

We agree and have updated.

¹³ In Europe and the United States, bone and joint TB accounts for 2.2–4.7 percent of all TB cases and roughly 10–15 percent of EPTB cases, whereas in developing countries, particularly Asia, the incidence of EPTB rises to 15–20 percent. Males and females have identical rates of infection with Mycobacterium tuberculosis until adolescence, following which males have a greater rate. For all ages, male rates became higher than female rates. Many developing countries' current notification rates for both sexes are comparable to those of industrialized countries in the mid-twentieth century, though the sex and age pattern is similar to that of industrialized countries today, with men's disease rates exceeding women's after the age of fifteen. These data raise the potential that tuberculosis cases among women in underdeveloped countries are underreported. The average age of tuberculous vertebral osteomyelitis patients is 45–60 years old. Nonetheless, some research show a bimodal age distribution, with two peaks, one between 20 and 30 years old, linked to immigration and/or HIV infection (60 percent of cases in one study), and the other between 60 and 70 years old. Simultaneous extraspinal involvement is seen in 5–50% of cases, while ¹⁶comitant lung illness is seen in 2.3–65% of cases. The development of symptoms in spinal TB is usually gradual, and the disease progresses slowly, albeit an early onset has been documented. Symptoms might last anywhere from two weeks to many years at the time of diagnosis. The typical symptom duration was at least 12 months in early studies, although more current articles report a symptom duration of 2–7 months. Pain is

common (83–100%), although only a third of individuals have a fever or other constitutional symptoms. Patients with extraspinal TB and those with disseminated disease are more likely to experience these symptoms. In tuberculosis of the upper limb, the elbow joint is the most commonly implicated joint. The incidence of elbow tuberculosis has been observed to range from 2 to 5% of all skeletal sites. There are only a few important reports on TB of the elbow joint that have been published. There were no management options or classifications. Histopathology, AFB staining, and polymerase chain reaction (PCR) were all performed on the samples.

Pathogenesis

Reactivation of bacilli embedded in bone during the first mycobacteremia of primary infection causes tuberculous elbow and arthritis. The extensive vascular supply of the vertebra and growth plates of the long bones explains the bacillus' preference for the spine and major joints. Musculoskeletal tuberculosis develops as a result of the bacilli being seeded in the bloodstream shortly after the initial pulmonary infection. Osteoarticular tuberculosis begins as osteomyelitis in the growth plates of bones, where the blood supply is strongest, and subsequently spreads locally into joint spaces. It can also spread through the lymphatic system; however this is a less usual occurrence. The stimulation of dormant lymphatic or blood stream areas of morbidity might cause infections in joints. In the long bones, tuberculosis begins in the epiphysis and progresses to the marrow, where it causes tubercle formation and trabeculae infection. The mycobacteria cause an inflammatory response in the synovium of the joint, which is followed by the production of granulation tissue. The granulation tissue pannus then starts to erode and degrade cartilage and finally bone, resulting in demineralization. Proteolytic enzymes that damage peripheral cartilage aren't created because tuberculosis isn't a pyogenic infection. As a result, for a long period, the joint space is kept. Abscesses in the surrounding tissue may occur if the infection is allowed to proceed without treatment. Sequestration of bone is uncommon due to the absence of space-occupying exudates with substantial interruption of vascular supply. As a result, the active phase of tuberculous elbow is characterized by bone loss without sequestra and little new bone growth.

Please explain the sentence "The specific AFB smear and culture tests are still important, although they can occasionally show false negative results."

A negative AFB smear indicates that there is no infection, that symptoms are caused by anything other than mycobacteria, or that mycobacteria were not present in sufficient numbers to be detected under a microscope. In order to increase the likelihood of finding the organisms, at least three samples are usually taken. However, if AFB smears are negative but a strong suspicion of a mycobacterial infection remains, more samples may be taken and analyzed on different days. Because the culture media permits tiny amounts of germs to thrive and be detected, a smear negative sample can nonetheless grow mycobacteria. AFB smears that are positive suggest a mycobacterial infection. To confirm a diagnosis, however, a culture must be taken. AFB smear results are combined with results from the nucleic acid amplification test (NAAT) for TB in persons who have signs and symptoms of an active TB infection. Though a culture is required for a conclusive diagnosis, the results of the smear and NAAT may be useful in determining what to do.

Histopathology, AFB staining, and polymerase chain reaction all validated the diagnosis of elbow tuberculosis (PCR). Biopsy without affecting the bone's integrity. The histopathologic

results such as epitheloid infiltration, tubercle formation, caseous necrosis, and Langhan's giant cells confirmed the TB pattern.

Please mention the gold standard of diagnostics for bones or joint TB. Bone biopsy is the gold standard for diagnosis.


References :

- [1] Holmes CB, Hausler H, Nunn P. A review of sex differences in the epidemiology of tuberculosis. *Int J Tuberc Lung Dis.* 1998;2(2):96–104.
- [2] Dhillon M, Goel A, Prabhakar S, Aggarwal S, Bachhal V. Tuberculosis of the elbow: A clinikoradiological analysis. *Indian J Orthop.* 2012;46(2):200. DOI: <https://doi.org/10.4103/0019-5413.93684>
- [3] Haider Abdul-Lateef Mousa. Bones and Joints Tuberculosis. *Bahrain Med Bull.* 2007;29(1):17–21.
- [4] Pigrau-Serrallach C, Rodríguez-Pardo D. Bone and joint tuberculosis. *Eur Spine J.* 2013;22 Suppl 4(Suppl 4). DOI: <https://doi.org/10.1007/S00586-012-2331-Y>

Competing Interests: None

Reviewer Report 05 July 2021

<https://doi.org/10.5256/f1000research.56876.r88014>

 **2021 Rusli M.** This is an open access peer review report distributed under the terms of the [Creative Commons Attribution License](#), which permits unrestricted use, distribution, and reproduction in any medium, provided the original work is properly cited.



Musofa Rusli 

Department of Internal Medicine, Faculty of Medicine, Airlangga University, Surabaya, Indonesia

The background and risk factors of the case and the case's progression are sufficiently described. In addition, there are enough details provided of the physical examination, diagnostic tests, and brief outcome of the case. Furthermore, a good discussion is included of the importance of the findings and their relevance in managing the particular case. Finally, there is an adequate presentation of the clinical management to be useful for other practitioners.

However, some issues need to be taken into account. For example, it is better to use a proofreading service to correct some typographical mistakes. In the Case Report Section, the source of sample in the sentence "histopathological examination was also performed" needs to be clarified; is it from the pus or other tissue?

Below are some references worth considering to be included in the manuscript:

- Boodoo *et al.* (2020¹)
- Liao *et al.* (2017²)

References

1. Boodoo KN, Lillis R: Osteoarticular tuberculosis involving the elbow. *Oxf Med Case Reports*. 2020; **2020** (10): omaa085 [PubMed Abstract](#) | [Publisher Full Text](#)
2. Liao Q, Shepherd JG, Hasnie S: Mycobacterium tuberculosis of the elbow joint. *BMJ Case Rep*. 2017; **2017**. [PubMed Abstract](#) | [Publisher Full Text](#)

Is the background of the case's history and progression described in sufficient detail?

Yes

Are enough details provided of any physical examination and diagnostic tests, treatment given and outcomes?

Yes

Is sufficient discussion included of the importance of the findings and their relevance to future understanding of disease processes, diagnosis or treatment?

Yes

Is the case presented with sufficient detail to be useful for other practitioners?

Yes

Competing Interests: No competing interests were disclosed.

Reviewer Expertise: Infectious disease

I confirm that I have read this submission and believe that I have an appropriate level of expertise to confirm that it is of an acceptable scientific standard.

Author Response 13 Jul 2021

Desdiani Desdiani, Universitas Sultan Ageng Tirtayasa, Cilegon, Indonesia

Dear Dr. Musofa Rusli,

Thank you for allowing us the opportunity to submit a revised draft of the manuscript "Case Report: Delayed treatment of tuberculosis of the elbow joint" for publication in the F1000Research.

We appreciate the time and effort that you dedicated to providing feedback on our manuscript and are grateful for the insightful comments and valuable improvements to our paper. We have incorporated most of the suggestions made by the reviewers. Please see below, for a point-by-point response to the reviewers' comments and concerns:

1. We have used a proofreading service to correct some typographical mistakes with scribendi.com
2. The source of the sample for histopathological examination was taken from white granulation tissue on the posterior region of *cubiti sinistra*.

3. We are agree that references such as Voodoo et al. (2020) and Liao et al. (2017) can be used for comparison of clinical, histopathological and radiological findings with the patients we analyzed and reported at this time.

Thank you so much,
Best Regards,

Desdiani Desdiani

Competing Interests: No competing interests were disclosed.

Author Response 15 Jun 2022

Desdiani Desdiani, Universitas Sultan Ageng Tirtayasa, Cilegon, Indonesia

Dear Musofa Rusli,
Thank you for your respond and review.

Best Regards,
Desdiani Desdiani

Competing Interests: No competing interests were disclosed.

The benefits of publishing with F1000Research:

- Your article is published within days, with no editorial bias
- You can publish traditional articles, null/negative results, case reports, data notes and more
- The peer review process is transparent and collaborative
- Your article is indexed in PubMed after passing peer review
- Dedicated customer support at every stage

For pre-submission enquiries, contact research@f1000.com

F1000Research

Case Report: Delayed treatment of tuberculosis of the elbow joint [version 2; peer review: 2 approved]

ORIGINALITY REPORT

8%

SIMILARITY INDEX

4%

INTERNET SOURCES

5%

PUBLICATIONS

5%

STUDENT PAPERS

PRIMARY SOURCES

- | | | |
|---|---|-----|
| 1 | Submitted to University of Hertfordshire
Student Paper | 2% |
| 2 | Submitted to Logan University
Student Paper | 1% |
| 3 | pubmed.ncbi.nlm.nih.gov
Internet Source | 1% |
| 4 | Isabel León Rubio, Guerrero Espejo.
"Decrease in osteoarticular tuberculosis in Spain between 1997 and 2018", Reumatología Clínica (English Edition), 2023
Publication | <1% |
| 5 | Kim, Jun Ho, Soon Gu Cho, Kwang Ho Kim, Yeo Ju Kim, In Young Hyun, and Kyung Hee Lee.
"Multifocal Skeletal Tuberculosis Mimicking Metastasis Involving the Sternum, Lumbar Vertebra, and Sacrum", Journal of the Korean Society of Radiology, 2010.
Publication | <1% |

6

G.B. Migliori, R. Centis, L. Fattorini, G. Besozzi, C. Saltini, G. Orefici, C. Piersimoni, A. Gori, A. Cassone. "Monitoring the quality of laboratories and the prevalence of resistance to antituberculosis drugs: Italy, 1998–2000", *European Respiratory Journal*, 2003

Publication

<1 %

7

www.phac-aspc.gc.ca

Internet Source

<1 %

8

Submitted to American University of Beirut

Student Paper

<1 %

9

Archibald, Lennox K., and Ronald G. Quisling. "Central Nervous System Infections", *Textbook of Neurointensive Care*, 2013.

Publication

<1 %

10

George Sikalengo, Adria Ramirez, Diana Faini, Kim Mwamelo et al. "Tuberculous spondylitis diagnosed through Xpert MTB/RIF assay in urine: a case report", *BMC Infectious Diseases*, 2016

Publication

<1 %

11

Prashant R Tembhare, Harshini Sriram, Gaurav Chatterjee, Twinkle Khanka et al. "Comprehensive immune cell profiling depicts an early immune response associated with severe coronavirus disease 2019 in cancer patients", *Immunology & Cell Biology*, 2021

Publication

<1 %

12 Submitted to Utica College <1 %
Student Paper

13 Submitted to University of Dundee <1 %
Student Paper

14 www.mdpi.com <1 %
Internet Source

15 www.pubfacts.com <1 %
Internet Source

16 Sameena Khan, Chanda Vyawahare, Shahzad Mirza, Nageswari R. Gandham, Sahjid Mukhida. "Lest we forget Spinal tuberculosis (Potts's spine): Case Series with unusual presentation", Indian Journal of Tuberculosis, 2022
Publication

17 Mandeep S Dhillon, Ravi Kumar Gupta, Raj Bahadur, Onkar N Nagi. "Tuberculosis of the sternoclavicular joints", Acta Orthopaedica Scandinavica, 2009
Publication

18 pure.uva.nl <1 %
Internet Source

19 A Faustini. "Risk factors for multidrug resistant tuberculosis in Europe: a systematic review", Thorax, 2006
Publication

Exclude quotes On

Exclude matches Off

Exclude bibliography On