

# The Case Report of A Covid-19 Patient with Late Diagnosis of HIV

*by* Desdiani Desdiani

---

**Submission date:** 02-May-2023 01:27PM (UTC+0800)

**Submission ID:** 2081777347

**File name:** document.pdf (175.83K)

**Word count:** 2956

**Character count:** 15964



16

**ACITYA WISESA (Journal of Multidisciplinary Research)**<https://journal.jfpublisher.com/index.php/jmr>

Vol. 2 Issue. 2 (2023)

[doi.org/10.56943/jmr.v2i2.302](https://doi.org/10.56943/jmr.v2i2.302)

## The Case Report of A Covid-19 Patient with Late Diagnosis of HIV

**Desdiani**[desdiani@ymail.com](mailto:desdiani@ymail.com)

21

Faculty of Medicine, Universitas Sultan Ageng Tirtayasa, Banten

### ABSTRACT

*Coronavirus 2019 (Covid-19) is a disease that causes hyper-systemic inflammation affecting the respiratory system and extrapulmonary system. Covid-19 causes non-specific clinical health disorders in immunocompromised patients who often do not react to treatment. One case of a 58-year-old Indonesian man with a positive GeneXpert test result for Covid-19 but did not react to routine Covid-19 first-line therapy. The patient's anti-HIV test was confirmed positive, with an absolute CD4 of 13.7 cells/L, lactate dehydrogenase of 385 U/L, and procalcitonin of 0.24 ng/mL. The patient was treated with antibiotics, remdesivir, dexamethasone, heparin, anti-HIV treatment, and other supporting medications. The PCR test was negative ten days later, the laboratory and radiology results had also stabilized. In this case, the possibility of co-detection of Covid-19 with immune system diseases such as HIV is emphasized, and the importance of further testing for suspected patients to provide accurate treatment. It is quite difficult to determine HIV risk factors, and the limited treatment options for Covid-19 and it may not be effective. This case highlighted the possibility of misdiagnosis, especially during an infectious disease pandemic, and the importance of extended testing, even if the immunological state is disregarded in immune-compromised patients.*

**Keywords:** Covid-19, Co-infection, HIV, Late Diagnosis

## INTRODUCTION

20  
SARS CoV2 or commonly known as Severe Acute Respiratory Syndrome Coronavirus 2 which is a virus that causes Covid-19. The main suspect of being infected with Covid-19 is from infected patients, both those with symptoms and those without symptoms (Efriza, 2021). The symptoms suffered by Covid-19 patients are various, such as cough, fever, lethargy, reduced lymphocytes, pneumonia, and a ground-glass appearance on lung radiography (Organization, 2020). Covid-19 has spread to all countries in the world and was declared as a pandemic by the World Health Organization on March 11, 2020. In addition, WHO also stated that preventative steps that can be taken are washing hands with soap, using hand sanitizers, reducing public mobility, and using masks (Aditia, 2021). There are about 219,357,249 confirmed cases of Covid-19 that occurred worldwide since September 2, 2021. The total number also includes the total cases in Indonesia, which is around 4,109,093 cases. Then, around 134,356 people suffered with this virus which caused to death (Force, 2022; Republik Indonesia, 2021). The ongoing Covid-19 pandemic has delayed HIV diagnosis and treatment all over the world (Organization, 2021). Along with substantial progress in reducing the number of new HIV infections through low-threshold HIV testing, treatment as prevention (TasP) and initiation of HIV pre-exposure prophylaxis, the ongoing COVID-19 pandemic has led to major concerns in keeping high quality standards accessible, potentially increasing the rate of HIV transmission and also increasing the number of late HIV diagnoses (Bremen et al., 2022). Meanwhile, HIV itself commonly known as a disease that infected the human immune system and it can be reach to advanced level of disease called Acquired Immunodeficiency Syndrome (AIDS) (Khalisha et al., 2022).

A nonbreathing oxygen face mask (NRM) is a device for delivering low-velocity oxygen to patients who are able to breathe spontaneously. The NRM features a pure oxygen reservoir component and a one-way exhalation valve which allows delivery of high concentration oxygen to the patient (FiO<sub>2</sub> approximate around 90%). The act of administering oxygen therapy at a concentration higher than the concentration of oxygen in free air, for example by using a nasal cannula and nonbreathing oxygen face mask (NRM), is a procedure that is often performed in the management of emergency patients. This aims to overcome or prevent hypoxemia thereby increasing the availability of oxygen to body tissues. The amount and method of oxygen therapy administered is determined by the cause of the hypoxemia and the characteristics of the patient's respiratory failure.

Additional medications were given to the patient, such as oxygen nonbreathing mask 15 liters/minutes; intravenous remdesivir 200 mg once on the first day and 100 mg once on the following days; azithromycin 500 mg once daily; intravenous dexamethasone 7.5mg once daily; enoxaparin 0.4 CC once daily; and

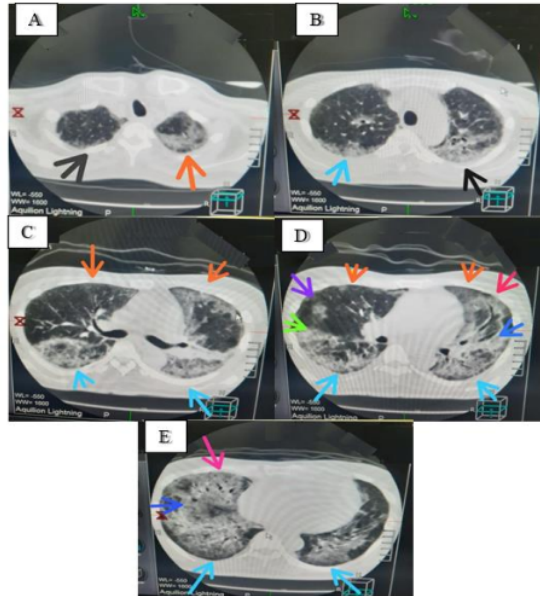
anti-HIV treatment. The RT-PCR test result was negative ten days later. The patient had no complaint, was improving clinically, and was scheduled to be discharged.

## RESEARCH METHODOLOGY

The method used in this research is prospective observational study which analyzed a case report of 58 years old Indonesian male was admitted to the pulmonary polyclinic with a dry cough for one month, he was also suffered fatigue, fever, and weight loss around 4 kilograms. He was diagnosed with pulmonary tuberculosis (TB) based on clinical, laboratory, sputum examination and radiology showing bilateral infiltrate.<sup>3</sup> The patient was treated for two months with a standard first-line oral regimen of rifampicin 450 mg once daily, isoniazid 300 mg once daily, pyrazinamide 1000 mg once daily, and ethambutol 1000 mg once daily (2HRZE), and other symptomatic medications. Two weeks later, the patient presented to the emergency room with worsening conditions, shortness of breath, hoarseness, yellow eyes, weak body, fever, 8-kilograms weight loss. Total bilirubin 7.43 (normal value: 0.20 – 1.30 mg/dL), direct bilirubin 6.95 (normal value: 0.00-0.40 mg/dL), indirect bilirubin 0.48 (normal value: 0.00-1.00 mg/dL), and Alanine transaminase (ALT)/Aspartate transaminase (AST) 58/72 (normal value: <37/<42 U/L). The TB treatment was then stopped, and he<sup>12</sup> was admitted for inpatient care. The patient was given the analogue of natural Schisandrin C o<sup>25</sup> dimethyl-4,4'-dimethoxy-5,6, 5',6-dimethylene dioxybiphenyl-2,2'-dicarboxylate (HpPro) 7.5 mg three times daily and other symptomatic medications.

On physical examination, crackles were heard in both lung fields, but no wheezing was noted, despite his oxygen saturation being 99% in the room air. He had no comorbidities in his medical history<sup>3</sup> (e.g. hypertension, diabetes mellitus, autoimmune disease, or malignancy). The erythrocyte sedimentation rate (ESR)<sup>12</sup> 154 mm/hour (normal range: 0-10 mm/hour), the leukocyte count was 3.470 (normal range: 5000-10,000 cells/l), the hemoglobin level was 10 g/dL (normal range: 13,5-17,5 g/dL) and PCR test was negative. Three days later, the patient had a deteriorating condition, dyspnoea, fatigue, fever, and was tested for GeneXpert as the PCR test was negative but the chest X-ray indicated increased infiltrates. Antibiotics were administered with 750 mg of intravenous levofloxacin once per daily. Oxygen saturation reached 85 % of room air after two days, but<sup>26</sup> the patient's family refused intubation. Abnormalities in D-dimer value of 1.74 (normal range: 0-0.55 mg/L), fibrinogen >358 (normal range: 210-358 mg/dL), and ESR >150 (normal range: 0-10 mm/h) were found during coagulation laboratory evaluation. Based on a positive GeneXpert test for Covid-19 with CT ORF1ab Gen 19.14, Gen N 19.21 values, the patient was diagnosed with Covid-19 and HIV with clinical manifestations of nonproductive cough, fever, dyspnoea, bilateral interstitial infiltrates and hypoxemia, and a positive HIV test with an absolute CD4 of 13.7 cells/L, lactate dehydrogenase 385 U/L, and procalcitonin 0.24 ng/mL. The chest

CT scan without intravenous contrast indicated large ground-glass opacities (GGO) in both lungs which represented in Figure 1.



**Figure 1.** The chest CT scan thorax without intravenous contrast revealed large GGO in both lungs: (A) S1 right/black arrow, S1/2 left/orange arrow; (B) S2 right/blue arrow, S1/2 left/black arrow; (C) S6 right and left/blue arrow, S3 right and left/orange arrow; (D) S6 right and 5 left/light blue arrow, S7 right/light green arrow, S5 right/purple arrow, S3 right and left/orange arrow, S4 left/red arrow, S 7/8 left/blue arrow; (E) S9/10 right and left/light blue arrow, S7/8 right/blue arrow, S4/5 right/red arrow.

Meanwhile, additional medications administered to the patient were a 15 liter/minute nonbreathing oxygen mask, intravenous remdesivir 200 mg once on the first day and 100 mg once on subsequent days, azithromycin 500 mg once daily, intravenous dexamethasone 7.5 mg once daily, enoxaparin 0.4 cc once daily, and anti-HIV treatment. The RT-PCR test result was negative ten days later. The patient had no complaints, improved clinically, and was scheduled for discharge.

## RESULT AND DISCUSSION

This is the first time the researcher have found Covid-19 with HIV co-infection. HIV-positive people with low CD4+ T cell counts may be protected from the cytokine storms seen in Covid-19 patients which according to previous research. HIV-positive people with low CD4+ T cell counts may be immune to the cytokine storms found in Covid-19 patients (Vizcarra et al., 2020). SARS-CoV-2-specific T cells are important in the development of Covid-19 and T cell activity is reduced in people with severe disease (Riou et al., 2021). A positive HIV test result was found

in our patient, who had an absolute CD4 count of 13.7 cells/L. The patient was treated with additional medication, anti-HIV treatment and improved well clinically over ten days later.

There are two cases of HIV and SARS-CoV-2 co-infection described in Zhang's research. When these individuals were admitted, they had no clinical indications of HIV/AIDS, and Covid-19 therapy options were limited. The patients were given various treatments, but none were successful. This led to new concerns as to whether the patients' immune systems were functioning properly. A combined antigen/antibody test was tested as a consequence. An HIV test was done, and the result was positive. There were no blood transfusions or drug overdoses based on medical records. Another way to spread the disease is by sharing infected syringes. Although they are men who have sex with men (MSM), they are definitely tested positive for HIV. According to the local epidemic guidelines, patients are required to get antiretroviral drugs and proper follow-up at designated hospitals. In our case report, it was difficult to determine HIV risk factors. The patient stated that he had no previous experience with blood transfusion, drug overdose, casual sex, or MSM behavior. When the patient was brought to the hospital with severe Covid-19 and no response to treatment, he was recently diagnosed of HIV (Zhang et al., 2020).

Calza et al (2021) stated that during the observation period, HIV-positive individuals accounted for 3.4 percent of all hospitalized patients with a diagnosis of SARS-CoV-2 infection. These researchers only included Covid-19 patients co-infected with HIV among their hospitalized subjects, not non-hospitalized co-infected patients. In addition, not all HIV-positive patients in their clinic were tested for SARS-CoV-2, and there are most probably many cases of asymptomatic SARS-CoV-2 infection among HIV-positive people, such as in the general population, so these findings should be construed with caution. According to Zhu's research (2020), patients with HIV/SARS-CoV-2 co-infection had significant clinical and radiologic improvement after oral therapy with anti-HIV drugs, lopinavir/ritonavir 400/100 mg per dose twice daily for 12 days and moxifloxacin 400 mg once daily for 7 days,  $\gamma$ -globulin 400 mg/kg once daily for 3 days, and methylprednisolone 0.8 mg/kg once daily for 3 days through the intravenous route. In our case report, the patient was given anti-HIV treatment, levofloxacin, and dexamethasone, and recovered after ten days of treatment.

We described one case of SARS-CoV-2 and HIV co-infection in which the patient was recently diagnosed with HIV when he was hospitalized with severe COVID-19 and no response to treatment. Due to GeneXpert being used extensively in a variety of settings, the evaluation of the newly developed SARSCoV-2/Flu/RSV combination test is critical. GeneXpert performs a rapid, fully automated, and self-contained multiplex RT-qPCR test with a run time of <50 minutes. This patient had experienced a deteriorated condition, dyspnoea, fatigue, fever, and was tested by GeneXpert because the PCR test was negative but the chest X-ray indicated increased infiltrates (Johnson et al., 2021).

## CONCLUSION

In this case, it is quite difficult to determine HIV risk factors, and the limited treatment options for Covid-19 and it may not be effective. These patients were given remdesivir, which is covered by national insurance and available to everyone in our country, but other antiviral alternatives are difficult to obtain and expensive. Remdesivir was found to be superior to placebo in reducing the duration of recovery in individuals who were hospitalized for Covid-19 and had evidence of lower respiratory tract infection on Remdesivir's final report (Beigel et al., 2020). Our case report has several limitations. First, our findings are based on only one patient; larger observational studies are required to confirm our findings. The second is that we were unable to conduct further clinical follow-up because the patient continued his treatment at an HIV treatment center. This case highlighted the possibility of misdiagnosis, especially during an infectious disease pandemic, and the importance of extended testing, even if the immunological state is disregarded in immunocompromised patients.

## ACKNOWLEDGEMENT

The case report was presented as poster presentation at the Asian Pacific Society of Respiriology conference in 2021 (Abstract ID: 1858; Subject No: P5-150).

## REFERENCES

- Aditia, A. (2021). Covid-19: Epidemiologi, Virologi, Penularan, Gejala Klinis, Diagnosa, Tatalaksana, faktor Risiko dan Pencegahan. *Jurnal Penelitian Perawat Profesional*, 3(4), 653–660.
- Beigel, J. H., Tomashek, K. M., Dodd, L. E., Mehta, A. K., Zingman, B. S., Kalil, A. C., Hohmann, E., Chu, H. Y., Luetkemeyer, A., Kline, S., Castilla, D. L. de, & Finberg, R. W. (2020). Remdesivir for the Treatment of Covid-19 - Final Report. *N Engl J Med*, 383(19), 1813–1826. <https://doi.org/10.1056/NEJMoa2007764>
- Bremen, K. Van, Monin, M., Schlabe, S., Bischoff, J., & Rieke, G. J. (2022). Impact of COVID-19 on HIV late diagnosis in a specialized German centre. *HIV Medicine*, 23(11). <https://doi.org/https://doi.org/10.1111/hiv.13426>
- Calza, L., Bon, I., Tadolini, M., Borderi, M., Colangeli, V., Badia, L., Verucchi, G., Rossini, G., Vocale, C., Gaibani, P., Viale, P., & Attard, L. (2021). COVID-19 in patients with HIV-1 infection: a single-centre experience in northern Italy. *Infection*, 49, 333–337. <https://doi.org/https://doi.org/10.1007/s15010-020-01492-7>
- Efriza. (2021). Covid-19. *BRMJ: Baiturrahmah Medical Journal*, 1(1), 60–68.
- Force, C.-19 H. T. (2022). *Task Force for Covid-19 Handling Circular Number 24 of 2022 on Provisions for Domestic Travels Amid Corona Virus Disease 2019 (COVID-19) Pandemic*. <https://covid19.go.id/storage/app/media/Regulasi/2022/September/Taskforce Covid-19 Circular No. 24 Of 2022 On Provisions For Domestic Travels.pdf>
- Johnson, G., Zubrzycki, A., Henry, M., Ranadheera, C., Corbett, C., Meyers, A. F. A., Sandstrom, P. A., & Becker, M. G. (2021). Clinical evaluation of the GeneXpert® Xpert® Xpress SARS-CoV-2/Flu/RSV combination test. *Journal of Clinical Virology Plus*, 1(1–2). <https://doi.org/https://doi.org/10.1016/j.jcvp.2021.100014>
- Khalisha, M., Akbar, M. I. A., & Lestari, P. (2022). The Profile of HIV Infected Pregnant Woman in Tertiary Hospital. *LUX MENSANA: Journal of Scientific Health*, 1(4). <https://journal.jfpublisher.com/index.php/jsh/article/view/216>
- Organization, W. H. (2020). *Coronavirus Disease 2019 (COVID-19) Situation Report-92 on 21 April 2020*. [https://www.who.int/docs/default-source/coronaviruse/situation-reports/20200421-sitrep-92-covid-19.pdf?sfvrsn=38e6b06d\\_8](https://www.who.int/docs/default-source/coronaviruse/situation-reports/20200421-sitrep-92-covid-19.pdf?sfvrsn=38e6b06d_8)
- Organization, W. H. (2021). *HIV/AIDS*. World Health Organization. [https://www.who.int/health-topics/hiv-aids#tab=tab\\_1](https://www.who.int/health-topics/hiv-aids#tab=tab_1)
- Republik Indonesia, K. K. (2021). *Peta Sebaran Covid-19*. PHEOC Kemkes RI.



<https://covid19.go.id/peta-sebaran>

- Riou, C., Bruyn, E. du, Stek, C., Daroowala, R., Goliath, R. T., Abrahams, F., Said-Hartley, Q., Allwood, B. W., Hsiao, N. Y., Wilkinson, K. A., Arlehamn, C. S. L., Sette, A., Wasserman, S., & Wilkinson, R. J. (2021). Relationship of SARS-CoV-2-specific CD4 response to COVID-19 severity and impact of HIV-1 and tuberculosis coinfection. *JCI: The Journal of Clinical Investigation*, *131*(12), 1–15. <https://doi.org/https://doi.org/10.1172/JCI149125>
- Vizcarra, P., Pérez-Elías, M. J., Quereda, C., Moreno, A., Vivancos, M. J., Dronda, F., & Casado, J. L. (2020). Description of COVID-19 in HIV-infected individuals: a single-centre, prospective cohort. *The Lancet HIV*, *7*(8), 554–564. [https://doi.org/10.1016/S2352-3018\(20\)30164-8](https://doi.org/10.1016/S2352-3018(20)30164-8)
- Zhang, J.-C., Yu, X.-H., Ding, X.-H., Ma, H.-Y., Cai, X.-Q., Kang, S.-C., & Xiang, D.-W. (2020). New HIV diagnoses in patients with COVID-19: two case reports and a brief literature review. *BMC Infect Dis*, *20*(1).
- Zhu, F., Cao, Y., Xu, S., & Zhou, M. (2020). Co-infection of SARS-CoV-2 and HIV in a patient in Wuhan city, China. *Journal of Medical Virology*, *92*(6), 529–530. <https://doi.org/https://doi.org/10.1002/jmv.25732>

# The Case Report of A Covid-19 Patient with Late Diagnosis of HIV

## ORIGINALITY REPORT

18%

SIMILARITY INDEX

12%

INTERNET SOURCES

14%

PUBLICATIONS

5%

STUDENT PAPERS

## PRIMARY SOURCES

- 1 Giuliana Galassi, Alessandro Marchioni. "Acute neuromuscular syndromes with respiratory failure during COVID-19 pandemic: Where we stand and challenges ahead", *Journal of Clinical Neuroscience*, 2022  
Publication 2%
- 2 Ala Hussein Albawwat, Mohamad Yazis Ali basah. "Corporate Governance and Voluntary Disclosure of Interim Financial Reporting in Jordan", *Journal of Public Administration and Governance*, 2015  
Publication 1%
- 3 f1000research.com  
Internet Source 1%
- 4 clinicaltrials.gov  
Internet Source 1%
- 5 Yvette N. Lamb. "Remdesivir: First Approval", *Drugs*, 2020  
Publication 1%

|    |  |     |
|----|--|-----|
| 6  | Anna Rosa Garbuglia, Claudia Minosse, Paola Del Porto. "mRNA- and Adenovirus-Based Vaccines against SARS-CoV-2 in HIV-Positive People", <i>Viruses</i> , 2022<br>Publication   | 1 % |
| 7  | <a href="http://neuro.unboundmedicine.com">neuro.unboundmedicine.com</a><br>Internet Source  | 1 % |
| 8  | <a href="http://www.idstewardship.com">www.idstewardship.com</a><br>Internet Source  | 1 % |
| 9  | <a href="http://www.wjgnet.com">www.wjgnet.com</a><br>Internet Source  | 1 % |
| 10 | Grant Johnson, Arek Zubrzycki, Michele Henry, Charlene Ranadheera et al. "Clinical Evaluation of the GeneXpert® Xpert® Xpress SARS-CoV-2/Flu/RSV Combination Test", <i>Journal of Clinical Virology Plus</i> , 2021<br>Publication | 1 % |
| 11 | Grant Johnson, Arek Zubrzycki, Michele Henry, Charlene Ranadheera et al. "Clinical evaluation of the GeneXpert® Xpert® Xpress SARS-CoV-2/Flu/RSV combination test", <i>Journal of Clinical Virology Plus</i><br>Internet Source    | 1 % |
| 12 | <a href="http://ecam.oxfordjournals.org">ecam.oxfordjournals.org</a><br>Internet Source  | 1 % |

|    |  |      |
|----|--|------|
| 13 | Massimo Berger, Ivana Ferrero, Elena Vassallo, Luca Gastaldo, Francesca Carraro, Eleonora Biasin, Enrico Madon, Franca Fagioli. "STEM CELL TRANSPLANTATION AS CONSOLIDATION THERAPY FOR CHILDREN IN FIRST-REMISSION AML", <i>Pediatric Hematology and Oncology</i> , 2009<br>Publication | 1 %  |
| 14 | Desdiani Desdiani, Hidayat Rizal, Anindita Basuki, Fadilah Fadilah. "Case Report: Delayed treatment of tuberculosis of the elbow joint", <i>F1000Research</i> , 2021<br>Publication  | 1 %  |
| 15 | <a href="http://www.medrxiv.org">www.medrxiv.org</a><br>Internet Source  | 1 %  |
| 16 | <a href="http://www.openarchives.org">www.openarchives.org</a><br>Internet Source  | 1 %  |
| 17 | Franco Maggiolo, Fabio Zoboli, Marco Arosio, Daniela Valenti et al. "SARS - CoV - 2 infection in persons living with HIV: a single center prospective cohort", <i>Journal of Medical Virology</i> , 2020<br>Publication  | <1 % |
| 18 | <a href="http://amedeo.com">amedeo.com</a><br>Internet Source  | <1 % |
| 19 | Submitted to Imperial College of Science, Technology and Medicine  | <1 % |

20

[www.coursehero.com](http://www.coursehero.com)

Internet Source

<1 %

---

21

Desdiani Desdiani, Iris Rengganis, Samsuridjal Djauzi, Agus Setiyono et al. "Fibropreventive and Antifibrotic Effects of Uncaria gambir on Rats with Pulmonary Fibrosis", Evidence-Based Complementary and Alternative Medicine, 2022

Publication

<1 %

---

22

[bnrc.springeropen.com](http://bnrc.springeropen.com)

Internet Source

<1 %

---

23

[docplayer.net](http://docplayer.net)

Internet Source

<1 %

---

24

[reliefweb.int](http://reliefweb.int)

Internet Source

<1 %

---

25

[www.pubfacts.com](http://www.pubfacts.com)

Internet Source

<1 %

---

26

[www.spandidos-publications.com](http://www.spandidos-publications.com)

Internet Source

<1 %

---

27

Catherine Brahe, Rachel Ellis. "GOT SHINGLES? TEST FOR HIV. Severe shingles as first presenting infection in HIV/AIDS patient", IDCases, 2020

Publication

<1 %

---

---

Exclude quotes      On

Exclude matches      Off

Exclude bibliography      On