

Late diagnosis of COVID-19 in a 34-year-old man in a hypercoagulable state: A case report

by Desdiani Desdiani

Submission date: 13-Apr-2023 01:50PM (UTC+0800)

Submission ID: 2063248212

File name: e_diagnosis_of_COVID-19_in_a_34-year-old_man_in_CJRT_Journal.pdf (817.78K)

Word count: 2934

Character count: 16535

CASE REPORT

Late diagnosis of COVID-19 in a 34-year-old man in a hypercoagulable state: A case report

Desdiani Desdiani^{1,2}

D Desdiani. Late diagnosis of COVID-19 in a 34-year-old man in a hypercoagulable state: A case report. *Can J Respir Ther* 2022;58:49–52. doi: 10.29390/cjrt-2021-028.

Background: Late diagnosis of COVID-19 in young patients in a hypercoagulable state can cause a high mortality rate. Clinical manifestations of COVID-19 include respiratory and extra⁷monary symptoms such as a hypercoagulable state, increased transaminase enzymes, and multiple-organ failure.

Case and outcomes: A 34-year-old male presented to the emergency room after 3 days of high fever, weakness, and flatulence. The patient had thrombocytopenia and elevated liver transaminase enzymes and was initially diagnosed with dengue hemorrhagic fever. He was given hydration intravenous fluids, oxygen, antipyretic, and hepatoprotector. On day 4, the patient was diagnosed with COVID-19 and received therapy to decrease the Alanine transaminase and Aspartate transaminase levels. While waiting for outsourced D dimer and prothrombin time results, the patient was given low molecular weight heparin (LMWH) on day 5. On day 13, his condition deteriorated with cephalgia and shortness of breath, but the patient's family refused intubation. The chest CT scan revealed large ground-glass opacities in both lungs. The patient was given additional medications, such as Meropenem, Dexamethasone, and Remdesivir. On day 15, the patient passed away.

Discussion: Intermediate LMWH dosage seems to be associated with a lower mortality incidence than standard Deep Vein Thrombosis (DVT) prophylaxis in hospitalized COVID-19 patients. However, due to the late COVID-19 diagnosis, the patient was not given LMWH at the beginning of treatment.

Conclusion: A hypercoagulable state is partly responsible for the high mortality rate of COVID-19 patients. Early detection and management of the hypercoagulable state, including the use of LMWH, can decrease the severity of COVID-19 symptoms.

Key Words: COVID-19; hypercoagulable state; late diagnosis; LMWH; young patient

16

INTRODUCTION

COVID-19 is caused by a contagious virus that can lead to severe respiratory problems. The complications of thrombotic events frequently result in the deterioration of COVID-19 patients. Thrombotic and coagulation abnormalities can lead to a hypercoagulable state [1]. COVID-19 patients usually have shortness of breath, cough, and fever. Other frequent symptoms are sore throat, myalgia, fatigue, headache, rhinorrhea, and diarrhea [2]. Laboratory findings in COVID-19 patients generally indicate decreased lymphocyte and increased C-reactive protein (CRP). In cases with coagulopathy complications, there are increases in D-dimer, prolonged prothrombin time (PT), fibrinogen, lactate dehydrogenase, and ferritin²⁰ levels [3]. Radiologic evaluation of these patients frequently reveals ground-glass opacities (GGO) and bilateral multiple lobular and subsegmental consolidation [4].

This case report details a patient initially diagnosed with dengue hemorrhagic fever (DHF), who was then diagnosed with COVID-19 after 4 days of treatment and died after 15 days of hospitalization.

ETHICS APPROVAL

The patients' elder sister consented to the publication of this de-identified case report. Institutional review board approval is not required for de-identified single case reports or histories based on institutional policies.

8

¹Faculty of Medicine, Universitas Sultan Ageng Tirtayasa, Cilegon, Banten, Indonesia

²Department of Pulmonology and Respiratory Medicine, Bhayangkara Brimob Hospital, Cimanggis, Depok, West Java, Indonesia

Correspondence: Desdiani Desdiani, Faculty of Medicine, Universitas Sultan Ageng Tirtayasa, Jalan Jend. Sudirman No.20, RT.10/RW.5, Kotabumi, Cilegon, Banten, Indonesia 42434. Tel: (+62-254) 280330, Fax: (+62-254) 281254, E-mail: desdiani@gmail.com

Published online at <https://www.cjrt.ca> on 20 April 2022



This open-access article is distributed under the terms of the Creative Commons Attribution Non-Commercial License (CC BY-NC) (<http://creativecommons.org/licenses/by-nc/4.0/>), which permits reuse, distribution and reproduction of the article, provided that the original work is properly cited and the reuse is restricted to noncommercial purposes. For commercial reuse, contact editor@csrt.com

315 U/L (normal value: 12–38 U/L), and potassium level was 3.16 mmol/L (normal value: 3.7–5.2 mmol/L). The posteroanterior chest X-ray results did not show any radiological abnormalities in the heart and lungs.

On day 5, the D dimer examination was carried out, the sample was sent outside the hospital, and the results came 4 days later. Hospital facilities were limited and, at that time, the national insurance did not cover the test cost. While waiting for the D dimer and PT results, the patient was given low molecular weight heparin (LMWH). The patient was experiencing hypoxemic respiratory failure and was in a hypercoagulable state due to the hyper inflammation process associated with COVID-19.

On day 7 of the treatment, the patient's condition still did not improve. He experienced shortness of breath. The oxygen saturation was 90%–92% room air. Subsequently, he was subjected to oxygen therapy using a non-rebreathing mask of 15 L/min. Laboratory tests revealed an ALT level of 87 U/L and AST level of 91 U/L. Chest radiographs indicated no radiological abnormalities in the heart and lungs. The patient was given Azithromycin, Dexamethasone, Remdesivir, Ondansetron, Omeprazole, and supplements (e.g., Vitamin C, Zinc, and Vitamin D3), N-acetyl cysteine, multivitamins, and other supporting medications.

On day 13, the patient's condition declined. He experienced shortness of breath and suffered from fever, abdominal bloating, headache, and tingling of limbs. The oxygen saturation was 84% room air, requiring intensive care unit (ICU) treatment using high flow nasal cannula FiO₂ 100% flow 60 L/min.

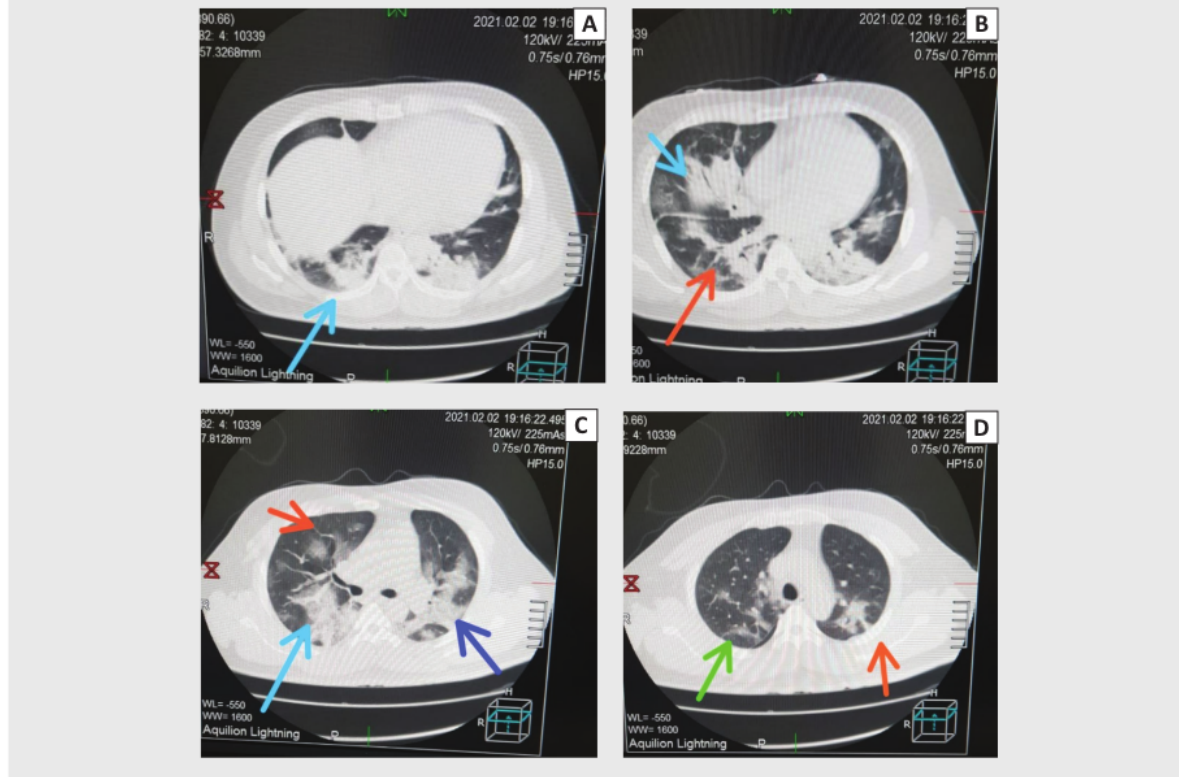
Intubation was recommended as a next step; after communication with the patient's family about this procedure, they refused based on the belief that intubation would further harm the patient. Although the patient was on heated high-flow oxygen and could communicate, the patient's family, especially the patient's elder sister, determined the treatment decisions. The patient deferred all decisions regarding medical treatment to the elder sister.

The laboratory tests revealed ESR of 95 mm/h, lymphocytes of 3%, NLR of 30.7, fibrinogen >500 mg/dL, D-dimers of 11,110 mg/L, ferritin of 2553 ng/L, and quantitative CRP of 75 mg/L. The chest CT scan without intravenous contrast revealed large GGO in both lungs, such as Segment 1 (S1) and S2 left; S2, S3, and S6 right; S4, S5, and S6 left; S4, S5, S7, S8 right; S10 right and left (Figure 1), representing anterior and posterior views of the pulmonary lobes and segments. The placement of the pulmonary segments and lobes on the anterior surface of the right and left lungs are depicted in a schematic drawing superimposed on a three-dimensional surface reformatted picture produced with a multidetector CT scanner. The apical (S1) and anterior (S3) segments of the right upper lobe, the lateral (S4) and medial (S5) segments of the right middle lobe, and the anterior basal (S8) segment of the right lower lobe make up the anterior surface of the right lung. The apicoposterior segment (S1 + S2), anterior (S3) segment, superior (S4) and inferior (S5) lingular segments of the left upper lobe, as well as the anteromedial segment (S6), the lateral basal (S9), and posterior basal (S10) segments.

The patient was then given additional medications, including Meropenem, Dexamethasone, Remdesivir, Ondansetron, Omeprazole,

FIGURE 1

The chest CT scan without intravenous contrast revealed large ground-glass opacities in both lungs: (A) S 10 right and left; (B) S4, S5, S7, S8 right/blue arrows and S10 right and left/orange arrows; (C) S3 right/orange arrow, S2, S4, S5, S6 right/blue arrow, S4, S5, S6 left/blue arrow; (D) S2 right/green arrow, S1 dan S2 left/orange arrow.



and supplements (e.g., Vitamin C, Zinc, and Vitamin D3). The patient's condition worsened, and the family still refused intubation. On the 15th day, the patient passed away. The cause of death was hypoxic respiratory failure, a hypercoagulable state due to the hyperinflammation process of COVID-19. A post mortem exam was not conducted because the family did not approve it.

DISCUSSION

A hypercoagulable state has been reported in COVID-19 patients with poor clinical conditions [1]. Several studies have shown that the pulmonary thrombosis rate of these patients reaches nearly 79% [5]. The thrombosis rate data comes from patients in non-ICUs and ICU. The study reported that the incidence of thrombosis in COVID-19 patients admitted to the ICU is about 31%–79% higher than that of non-ICU patients [1, 5]. Another study reported that the incidence of thrombosis in non-ICU patients increased from 9.2% to 15% [6]. In addition, the autopsy findings of COVID-19 patients showed that 58% of patients had undetected venous thrombosis that directly caused a severe pulmonary embolism in four of those patients [7]. The findings of this study are important because pulmonary thromboembolism is usually caused by bacteria or other viral pneumonia (only 1%–2.6%) [8]. In our case report, the patient had no history of comorbidities. Several studies have concluded that compared with patients receiving treatment in non-ICU wards, critically ill patients have higher risk factors for hypercoagulability and thrombosis [1, 5].

Increased proinflammatory and anti-fibrinolytic conditions were observed in patients with severe infection. A retrospective multicentre cohort study found that 54 COVID-19 patients who died were more likely to have low levels of lymphocytes, increased D-dimers, interleukin-6, cardiac troponin, ferritin, and lactate dehydrogenase [9]. Patients with coagulopathy complications have higher D-dimer levels [3].

In searching the current literature, no previous studies were found on the association between D-dimer increase and prediction of the level of severity of hypercoagulation complications, level of COVID-19 severity of the patients in the ICU, and potential mortality. The elevation of the transaminase enzyme in these patients is related to the incidence of liver injury in COVID-19. This liver injury, including systemic inflammatory, hypoxia, ischemia-reperfusion liver injury, and drug-induced hepatotoxicity, may direct injury from the virus to the liver [10]. This case report found increased transaminase enzymes, hypercoagulation conditions such as increased D-dimer, moderate thrombocytopenia, and prolonged PT.

The first mechanism of the pathophysiology of hypercoagulability in COVID-19 is vascular endothelial injury. Vascular endothelial cells are important for regulating vascular permeability, maintaining hemostasis, and regulating hemolysis. Vascular endothelial injury due to the infection of the SARS CoV-2 virus can cause primary pulmonary thrombus [11]. The second mechanism is the formation of microvascular microthrombi, which triggers the expression of active tissue factors in macrophages and endothelial cells. The increase in tissue hypoxic factors due to acute respiratory distress syndrome leads to an inflammatory process as a cytokine storm. The laboratory results of COVID-19 patients with hypercoagulation conditions indicate increased D-dimer, moderate thrombocytopenia, and prolonged PT [3]. Increased serum lactate dehydrogenase and ferritin levels are related to a high risk of death and microangiopathy in thrombotic complications of COVID-19 patients [9]. In this case report, we found increased transaminase enzymes, hypercoagulation conditions such as increased D-dimer, moderate thrombocytopenia, and prolonged PT due to hyperinflammatory reactions and vascular endothelial injury.

The use of LMWH for prophylaxis of venous thromboembolism has been approved by the World Health Organization for hypercoagulation management [12]. Besides having an anticoagulant effect, LMWH has demonstrated anti-inflammatory attributes that might be helpful against inflammatory conditions caused by the COVID-19 virus. Heparin also suppresses interleukin-6 reaction and interleukin-8 expression of lung epithelial cells, thereby reducing the risks of the emergence of thrombotic complications and cytokine storms [13]. Intermediate LMWH

dosage seems to be associated with a lower incidence of mortality compared to standard DVT prophylaxis in hospitalized COVID-19 patients. In this case, the patient had been given LMWH, but not at the beginning of treatment; therefore, the administration of LMWH did not seem to improve the patient's condition [14].

CONCLUSION

Late diagnosis of COVID-19 in young patients with a hypercoagulable state can cause high mortality rates. Further studies are required to understand the pathophysiology of hypercoagulation conditions in young patients. The role of laboratory results such as elevated D-dimer, ferritin, CRP and fibrinogen, thrombocytopenia and CT scan results help identify the hypercoagulable state. The relationship between hypercoagulation conditions and thrombotic complications in COVID-19 patients is unclear. However, it is clear that the state of hypercoagulation is partly responsible for the high mortality rate of COVID-19 patients. The mechanisms of hypercoagulation involving inflammatory cytokines, vascular endothelial injury, and serum prococagulants have been frequently discussed and investigated. These data can help the early management of the hypercoagulable state to decrease the severity of COVID-19, although the data are still limited and require further studies. Early detection and management of a hypercoagulable state can be an effective way to prevent the increasing severity of COVID-19, including the use of LMWH prophylaxis.

DISCLOSURE

4

Author contributions

All authors contributed to the development of the manuscript and the care of the patient presented. All authors approved the final manuscript.

2. Declaration of conflicting interests

No conflicts of interest to declare.

Funding

The authors received no financial support for the research, authorship, and/or publication of this article.

3. Informed consent

Written informed consent for the publication of this case report was obtained from the patient's family. A copy of the consent form is available upon request.

Ethical approval

Institutional review board approval is not required for de-identified single case reports or histories based on institutional policies.

REFERENCES

1. Klok FA, Kruip MJHA, Van der Meer NJM, et al. Incidence of thrombotic complication in critically ill ICU patient with COVID-19. *Thromb Res* 2020;191:145–7. doi: 10.1016/j.thromres.2020.04.013.
2. Huang C, Wang Y, Li X, et al. Clinical features of patients infected with 2019 novel coronavirus in Wuhan, China. *Lancet* 2020;395(10223):497–506. doi: 10.1016/S0140-6736(20)30183-5.
3. Levi M, Thachil J, Iba T, Levy JH. Coagulation abnormalities and thrombosis in patients with COVID-19. *Lancet Haematol* 2020;7(6):e438–40. doi: 10.1016/S2352-3026(20)30145-9.
4. Sun Z, Zhang N, Li Y, Xu X. A systematic review of chest imaging findings in COVID-19. *Quant Imaging Med Surg* 2020;10(5):1058–79. doi: 10.21037/qims-20-564.
5. Nahum J, Morichau-Beauchant T, Daviaud F, et al. Venous thrombosis among critically ill patients with coronavirus disease 2019 (COVID-19). *JAMA Netw Open* 2020;3(5):e2010478. doi: 10.1001/jamanetworkopen.2020.10478.
6. Middeldorp S, Coppens M, van Haaps TF, et al. Incidence of venous thromboembolism in hospitalized patients with COVID-19. *J Thromb Haemost* 2020;18(8):1995–2002. doi: 10.1111/jth.14888.
7. Wichmann D, Sperhake JP, Lu`tgehetmann M, et al. Autopsy findings and venous thromboembolism in patients with COVID-19. *Ann Intern Med* 2020;73(4):268–77. doi: 10.7326/M20-2003.

8. Ishiguro T, Kagiya N, Uozumi R, et al. Clinical characteristics of influenza-associated pneumonia of adults: clinical features and factors contributing to severity and mortality. *Yale J Biol Med* 2017;90(2):165-81.
 9. Zhou F, Yu T, Du R, et al. Clinical course and risk factors for mortality of adult inpatients with COVID-19 in Wuhan, China: a retrospective cohort study. *Lancet* 2020;395(10229):1054-62. doi: 10.1016/S0140-6736(20)30566-3.
 10. Zhong P, Xu J, Yang D, et al. COVID-19 associated gastrointestinal and liver injury: clinical features and potential mechanisms. *Signal Transduct Target Ther* 2020;5:256. doi: 10.1038/s41392-020-00373-7.
 11. McGonagle D, O'Donnell JS, Sharif K, Emery P, Bridgewood C. Immune mechanisms of pulmonary intravascular coagulopathy in COVID-19 pneumonia. *Lancet Rheumatol* 2020;2(7):e437-45. doi: 10.1016/S2665-9913(20)30121-1.
 12. WHO. Clinical management of COVID19: interim guidance. World Health Organization; 2020. Updated May 27, 2020. Available at: <https://www.who.int/publications-detail/clinical-management-of-covid-19> (Accessed March 1, 2020).
 13. Thachil J, Tang N, Gando S, et al. ISTH interim guidance on recognition and management of coagulopathy in COVID-19. *J Thromb Haemost* 2020;18(5):1023-6. doi: 10.1111/jth.14810.
 14. Paolisso P, Bergamaschi L, D'Angelo EC, Donati F, Gianella M, Tedeschi S. Preliminary experience with low molecular weight heparin strategy in COVID-19 patients. *Front Pharmacol* 2020;11:1124. doi: 10.3389/fphar.2020.01124.
-

Late diagnosis of COVID-19 in a 34-year-old man in a hypercoagulable state: A case report

ORIGINALITY REPORT

8%

SIMILARITY INDEX

4%

INTERNET SOURCES

6%

PUBLICATIONS

1%

STUDENT PAPERS

PRIMARY SOURCES

1	www.msjonline.org Internet Source	1%
2	acikerisim.afsu.edu.tr Internet Source	1%
3	cjm.cikd.ca Internet Source	1%
4	Barbara Resnick, Marie Boltz, Elizabeth Galik, Ashley Kuzmik, Jeanette Ellis, Chris Wells, Shijun Zhu. "Testing Function Focused Care for Acute Care using the Evidence Integration Triangle: Protocol description", Research in Nursing & Health, 2022 Publication	1%
5	Elliot B. Tapper, Shoshana J. Herzig. "Nondirected Testing for Inpatients With Severe Liver Injury", Journal of Hospital Medicine, 2017 Publication	1%
6	www.spandidos-publications.com Internet Source	<1%

7 Sunny Parmar, Jess Oren, Randle Storm, Jessica Hayden. "OUTPATIENT MANAGEMENT OF A PROTRACTED CASE OF HEART BLOCK DUE TO LYME CARDITIS UTILIZING AN EXTERNALIZED PERMANENT PACEMAKER", Journal of the American College of Cardiology, 2021
Publication

<1 %

8 www.phcogj.com
Internet Source

<1 %

9 Sheila D. Davis, Lawrence S. Yu, Keith D. Hentel. "Obliquely Oriented Superior Accessory Fissure of the Lower Lobe of the Lung: CT Evaluation of the Normal Appearance and Effect on the Distribution of Parenchymal and Pleural Opacities", Radiology, 2000
Publication

<1 %

10 addi.ehu.es
Internet Source

<1 %

11 Bingwen Eugene Fan, Christine Cheung. "Post COVID-19 Arterial Thromboembolism: A Clear and Present Danger", Seminars in Thrombosis and Hemostasis, 2021
Publication

<1 %

12 Fatimah Al-Ani, Samer Chehade, Alejandro Lazo-Langner. "Thrombosis risk associated

<1 %

with COVID-19 infection. A scoping review",
Thrombosis Research, 2020

Publication

13

Olivera Mitrović-Ajtić, Dragoslava Djikić, Tijana Subotički, Sandra Bižić-Radulović et al. "Sex difference in the cytokine profile among patients hospitalized for COVID-19 and during their recovery: predominance of females in adhesion molecules and males in oxidative stress", Research Square Platform LLC, 2022

Publication

14

Ricardo Wesley Alberca, Luana de Mendonça Oliveira, Anna Cláudia Calvielli Castelo Branco, Nátalli Zanete Pereira et al. "Obesity as a risk factor for COVID-19: an overview", Critical Reviews in Food Science and Nutrition, 2020

Publication

15

Rosaria Sofia, Mattias Carbone, Giovanni Landoni, Alberto Zangrillo, Lorenzo Dagna. "Anticoagulation as secondary prevention of massive lung thromboses in hospitalized patients with COVID-19", European Journal of Internal Medicine, 2022

Publication

16

helda.helsinki.fi

Internet Source

17

iris.paho.org

Internet Source

<1 %

<1 %

<1 %

<1 %

<1 %

18

Ahmed K. Pasha, Robert D. McBane, Rahul Chaudhary, Leslie J. Padrnos et al. "Timing of venous thromboembolism diagnosis in hospitalized and non-hospitalized patients with COVID-19", *Thrombosis Research*, 2021

Publication

<1 %

19

Thiago D. Stocco, Eliane Antonioli, Maria L. Romagnolli, Gustavo F. Sousa, Mario Ferretti, Anderson O. Lobo. "Aligned biomimetic scaffolds based on carbon nanotubes-reinforced polymeric nanofibers for knee meniscus tissue engineering", *Materials Letters*, 2020

Publication

<1 %

20

Zhonghua Sun, Nan Zhang, Yu Li, Xunhua Xu. "A systematic review of chest imaging findings in COVID-19", *Quantitative Imaging in Medicine and Surgery*, 2020

Publication

<1 %

Exclude quotes On

Exclude matches Off

Exclude bibliography On